

# Association of Wolfram syndrome with Fallot tetralogy in a girl

Hüseyin A. Korkmaz M.D.<sup>a</sup>, Korcan Demir M.D.<sup>a</sup>, Filiz Hazan M.D.<sup>b</sup>, Melek Yıldız M.D.<sup>c</sup>, Özlem N. Elmas M.D.<sup>a</sup> and Behzat Özkan Prof. Dr.<sup>a</sup>

## ABSTRACT

Wolfram syndrome (DIDMOAD: diabetes insipidus, diabetes mellitus, optic atrophy and deafness) is a rare neurodegenerative disorder. Mutations of the *WFS1* (wolframin) on chromosome 4 are responsible for the clinical manifestations in majority of patients with Wolfram syndrome. Wolfram syndrome is also accompanied by neurologic and psychiatric disorders, urodynamic abnormalities, restricted joint motility, cardiovascular and gastrointestinal autonomic neuropathy, hypergonadotrophic hypogonadism in males and diabetic microvascular disorders. There are very limited data in the literature regarding cardiac malformations associated in children with Wolfram syndrome. A 5-year-old girl with Wolfram syndrome and tetralogy of Fallot is presented herein.

**Key words:** Wolfram syndrome, Fallot tetralogy, DIDMOAD.

<http://dx.doi.org/10.5546/aap.2016.eng.e163>

## INTRODUCTION

First described in 1938 by Wolfram in four siblings, Wolfram syndrome (DIDMOAD) is a clinical condition involving concurrent diabetes insipidus, diabetes mellitus, optic atrophy and deafness.<sup>1</sup> Usually, diabetes mellitus is diagnosed initially and followed by optic atrophy within the first 10 years of life and diabetes insipidus and optic atrophy during the second decade.

Mutations on the *WFS1* gene on chromosome 4 are responsible for the clinical manifestations in majority of the patients with Wolfram syndrome.<sup>2</sup> This gene encodes an endoplasmic reticulum membrane protein (wolframin) present in neurons, pancreatic  $\beta$ -cells, internal ear, heart, placenta, lung and liver. Although the function

of this protein is unknown, its deficiency leads to increased stress within the endoplasmic reticulum, leading to impairment of cell cycle and calcium homeostasis. Wolframin has a role in maintaining the homeostasis of endoplasmic reticulum in pancreatic  $\beta$  cells.<sup>3</sup>

Cardiac malformations in Wolfram syndrome have been reported rarely<sup>4-7</sup> and may be responsible for the morbidity and mortality of the disorder. We present a case with Wolfram syndrome accompanied by tetralogy of Fallot and discuss the findings with reference to literature.

## CASE

A 5.3-year-old female patient presented with excessive thirst and frequent urination with 3 kg of weight loss during the last month. She had been diagnosed with Fallot tetralogy at 4 months of age and had undergone surgery. In addition, audiometric examination had revealed bilateral sensorineural hearing loss when she was 3-years old and she was receiving oxybutynin treatment at 0.2 mg/kg/day for neurogenic bladder for the last 4 months. She was the second child of apparently healthy non-consanguineous parents, born at full-term by normal vaginal delivery following an uncomplicated pregnancy. Family history did not disclose diabetes mellitus.

Physical examination: weight: 14.9 kg (3-10<sup>th</sup> percentile), height: 122 cm (50-75<sup>th</sup> percentile), strabismus, and surgical scars on the thorax. Laboratory: plasma glucose was 314 mg/dl, urinary ketone negative, normal blood gases, serum C-peptide level 0.18 pmol/ml (0.15-1.10) and HbA1c value of as 11.2% The diagnosis was diabetes mellitus. Anti-insulin antibody was 4.5 U (0-8 U), anti-GAD 0.9 U/ml (<1 U/ml), and islet cell antibody negative. She was discharged under four doses of regular insulin (0.73 U/kg/day) treatment.

At the age of seven and a half, despite good glycemic control (most recent HbA1c, 6.92%), she developed excessive thirst, frequent urination, and nocturnal enuresis. Fluid intake was estimated to be 3500 cc/m<sup>2</sup>/day and urine output 9.4 cc/kg/h. Renal function tests (BUN: 8.9 mg/dl, creatinine: 0.37mg/dl) and serum

- 
- a. Dr. Behçet Uz Children Disease and Surgery Training and Research Hospital, Department of Pediatrics, Division of Pediatric Endocrinology, Izmir, Turkey.  
b. Dr. Behçet Uz Children Disease and Surgery Training and Research Hospital, Department of Genetics, Izmir, Turkey.

E-mail address:

Huseyin A. Korkmaz, M.D.: drkorkmazanil@hotmail.com

Funding: None.

Conflict of interest: None.

Received: 9-3-2015

Accepted: 11-12-2015

electrolytes (Na: 139 mmol/L, C: 5.1 mmol/L, Cl: 105 mmol/L) were normal. Serum osmolality was 275 mOsm/kg, urine osmolality 168 mOsm/kg, and serum ADH level <0.5 pmol/L. Central diabetes insipidus was considered and treatment with desmopressin nasal spray was started (10 µg bid). Desmopressin nasal spray therapy resulted in a marked improvement of excessive thirst, frequent urination, and nocturnal enuresis. Fundus oculi examination demonstrated bilateral optic atrophy and no sign of diabetic retinopathy. Pituitary magnetic resonance imaging did reveal absence of bright spot in the posterior pituitary. Wolfram syndrome was diagnosed accordingly.

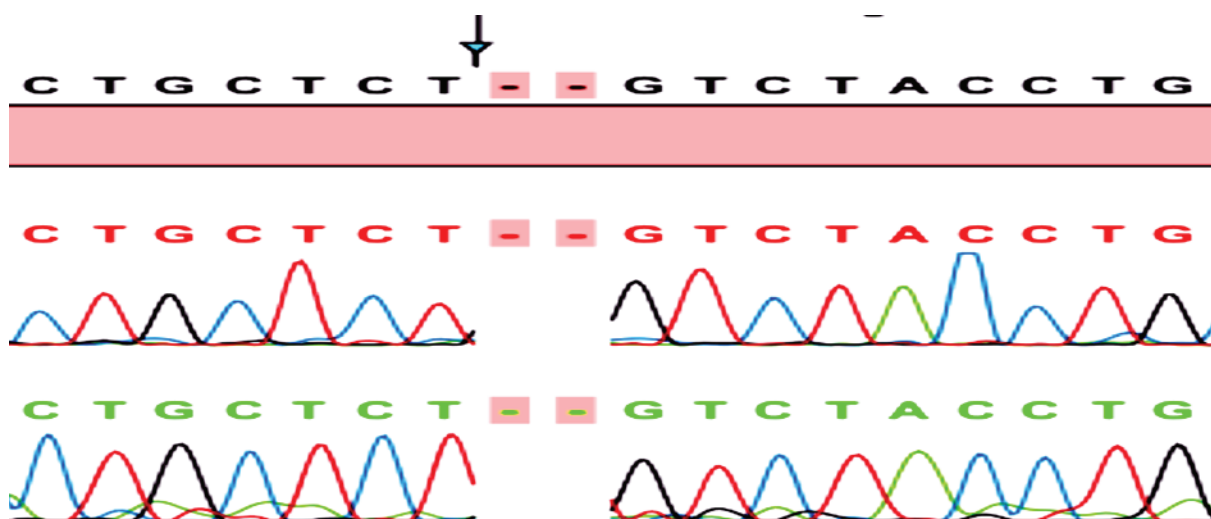
Genomic DNA from proband and parents were extracted from peripheral blood leukocytes using the QIAamp DNA mini kit (Qiagen, 51304, Dusseldorf, Germany), according to standard procedures. Genomic fragments including coding regions and adjacent intronic regions of *WFS1* were amplified with PCR, using previously described primers (genetic source). The amplicons were purified and analyzed with cycle sequencing with ABI BigDye Terminator Cycle Sequencing Kit v3.1 (ABI Applied Biosystems, Foster City, CA) on an automatic DNA sequencer (ABI 3130 Genetic Analyzer, Applied Biosystems). A known mutation (Y508fsX541, c.1523\_1524delAT) was homozygous in exon 8 of *WFS1* were detected in the proband (Figure 1). This mutation was present in heterozygous form in both parents.

## DISCUSSION

Various genetic alterations are responsible for Wolfram syndrome.<sup>8</sup> Majority of the cases have homozygous or compound heterozygote *WFS1* mutations resulting in altered function of wolframin. However, recently, a dominantly inherited *WFS1* mutation was found to underlie Wolfram syndrome in a Finnish family.<sup>9</sup> Mutations in *CISD2* have been identified in patients with a similar clinical picture but without diabetes insipidus (Wolfram syndrome 2).<sup>10</sup> Similar to wolframin, the *CISD2*-encoded protein ERIS (endoplasmic reticulum intermembrane small protein) localizes to endoplasmic reticulum.<sup>10</sup> Some patients with Wolfram syndrome demonstrate mutations at mitochondrial DNA.<sup>11,12</sup> Mitochondrial defects leading to diabetes mellitus are usually accompanied by neurovascular disorders including mental retardation, migraine, deafness and convulsions.<sup>12</sup> In our patient, Wolfram syndrome was associated with a homozygous mutation in *WFS1*.

Diabetes mellitus is generally the first clinical manifestation in Wolfram syndrome and develops during the first decade of life, at about 6 years of age in average. Since all of the features were not present, diagnosis of Wolfram syndrome could not be made in our patient at the onset of diabetes. Congenital rubella syndrome is known to be associated with type 1 diabetes, heart defects, sensory deafness, and cataracts.<sup>13</sup>

FIGURE 1. Chromatogram of the homozygous change, c.1523\_1524delAT, in the patient.



Our patient had not such a history, cataract, or autoantibodies for type 1 diabetes. Recently, *GATA6* mutations are reported to be a cause of severe congenital heart disease and neonatal/childhood-onset diabetes.<sup>14</sup> Our patient neither experienced decreased exocrine pancreas function nor hepatobiliary abnormalities that occur with *GATA6* mutations. Retrospectively, presence of congenital heart disease, sensorineural hearing loss in an autoantibody-negative child with diabetes and voiding dysfunction would have led to the diagnosis of Wolfram syndrome at the time of presentation since this rare association has been reported in relevant studies.

In a case series involving 31 Lebanese patients, valvular heart disease, particularly pulmonary stenosis, was detected in five (16.1%) and ventricular septal defect in one patient.<sup>4</sup> In a report from Turkey, ventricular septal defect was noted in some of the members of the family with Wolfram syndrome.<sup>5</sup> In a case series involving 68 patients with Wolfram syndrome, only three patients had cardiac anomalies: tetralogy of Fallot in two of them and pulmonary valve stenosis in one.<sup>6</sup> None of the abovementioned cases with cardiac abnormalities had undergone mutational analyses. Aloï et al., reported a Wolfram syndrome patient with surgically repaired tetralogy of Fallot due to a compound heterozygous mutation, c.1628T>G and c.2104G>A.<sup>7</sup> In the series by Strom et al., the patient harboring the mutation, as our patient, (c.1523delAT) exhibited a severe phenotype with an early onset of cardinal clinical manifestations including abnormal EEG and retarded sexual maturation. In the reported case, the finding of a *WFS1* mutation in exon 8 was not associated with a cardiac anomaly.<sup>15</sup> Our patient had neurogenic bladder dysfunction. In the series by Colosimo et al., the patient with c.1523delAT mutation showed a mild phenotype with urinary tract dilatation.<sup>11</sup> The mechanism underlying association of Wolfram syndrome with cardiac malformations is unknown. Further studies may help us understand the function of wolframin protein in development of cardiovascular system.

One limitation of our study was absence of water deprivation test for diagnosing diabetes insipidus according to serum and urine osmolality. The water deprivation test was planned to establish a diagnosis of diabetes insipidus, but her parents could not accept this test. Central diabetes insipidus was considered with good response to desmopressin nasal spray therapy,

absence of bright spot in the posterior pituitary and homozygous mutation in exon 8 of *WFS1*.

In summary, congenital heart defects can be a feature of Wolfram syndrome. This is particularly important for diagnostic approach of children with autoantibody-negative diabetes and incomplete features of Wolfram syndrome. Early diagnosis and appropriate management would prevent development of complications. ■

## REFERENCES

1. Barrett TG, Bunday SE, Macleod AF. Neurodegeneration and diabetes: UK nationwide study of Wolfram (DIDMOAD) syndrome. *Lancet* 1995;346(8988):1458-63.
2. Hattersley AT, Njolstad P, Bruining J, Shield J, et al. Monogenic diabetes. In: International Diabetes Federation. *Global IDF/ISPAD Guideline for Diabetes in Childhood and Adolescence*. Brussels: International Diabetes Federation; 2011:31-6. [Cited: 205 November 13]. Available from: <http://www.idf.org/sites/default/files/Diabetes-in-Childhood-and-Adolescence-Guidelines.pdf>
3. Hilson JB, Merchant SN, Adams JC, Joseph JT. Wolfram syndrome: a clinicopathologic correlation. *Acta Neuropathol* 2009;118(3):415-28.
4. Medlej R, Wasson J, Baz P, Azar S, et al. Diabetes mellitus and optic atrophy: a study of Wolfram syndrome in the Lebanese population. *J Clin Endocrinol Metab* 2004;89(4):1656-61.
5. Bekir NA, Gungör K, Güran S. A DIDMOAD syndrome family with juvenile glaucoma and myopia findings. *Acta Ophthalmol Scand* 2000;78(4):480-2.
6. Kinsley BT, Swift M, Dumont RH, Swift RG. Morbidity and mortality in the Wolfram syndrome. *Diabetes Care* 1995;18(12):1566-70.
7. Aloï C, Salina A, Pasquali L, Lugani F, et al. Wolfram syndrome: new mutations, different phenotype. *PLoS One* 2012;7(1):e29150.
8. Khanim F, Kirk J, Latif F, Barrett TG. *WFS1*/wolframin mutations, Wolfram syndrome, and associated diseases. *Hum Mutat* 2001;17(5):357-67.
9. Bonnycastle LL, Chines PS, Hara T, Huyghe JR, et al. Autosomal dominant diabetes arising from a wolfram syndrome 1 mutation. *Diabetes* 2013;62(11):3943-50.
10. Rigoli L, Di Bella C. Wolfram syndrome 1 and Wolfram syndrome 2. *Curr Opin Pediatr* 2012;24(4):512-7.
11. Colosimo A, Guida V, Rigoli L, Di Bella C, et al. Molecular detection of novel *WFS1* mutations in patients with Wolfram syndrome by a DHPLC-based assay. *Hum Mutat* 2003;21(6):622-9.
12. Hofmann S, Bezold R, Jaksch M, Kaufhold P, et al. Analysis of the mitochondrial DNA from patients with Wolfram (DIDMOAD) syndrome. *Mol Cell Biochem* 1997;174(1-2):209-13.
13. Takasu N, Ikema T, Komiya I, Mimura G. Forty-year observation of 280 Japanese patients with congenital rubella syndrome. *Diabetes Care* 2005;28(9):2331-2.
14. Gong M, Simaite D, Kühnen P, Heldmann M, et al. Two novel *GATA6* mutations cause childhood-onset diabetes mellitus, pancreas malformation and congenital heart disease. *Horm Res Paediatr* 2013;79(4):250-6.
15. Strom TM, Hörtnagel K, Hofmann S, Gekeler F, et al. Diabetes insipidus, diabetes mellitus, optic atrophy and deafness (DIDMOAD) caused by mutations in a novel gene (wolframin) coding for a predicted transmembrane protein. *Hum Mol Genet* 1998;7(13):2021-8.