ASSESSMENT OF MANIPULATION ACCURACY OF DIGITIZED OCCLUSAL RADIOGRAPHIC IMAGES - SUB AND OVER EXPOSURE

Patrícia S.L. Maschtakow, Mari E.L. Moraes, Milton G. Soares, Luis R.A. Santos, Luiz C. Moraes, Julio C.M. Castilho

Diagnosis and Surgery Department, São Paulo State University, São José dos Campos Dental School, SP, Brazil.

ABSTRACT

The aim of this study was to evaluate whether digitized images obtained from occlusal radiographs taken with low or over dose of radiation could be improved with the aid of computer software for digital treatment. Thirteen occlusal radiographs of a dry skull were taken employing 13 different exposure times. The radiographs were digitized and then manipulated with the program for image editing. 143 evaluations were performed by specialists in dental radiology who classified radiographs as appropriate or not appropriate for interpretation. Test Z was used for statistical analysis of the data and the results showed that it is possible to manipulate digitized radiographic images taken with 75% of the ideal exposure time and to make them suitable for interpretation and diagnosis. Conversely, it was concluded that the over exposed images, 57.50% above the standard exposure time, were inadequate.

Key words: radiographic image enhancement, image processing, computer-assisted radiography, dental radiography.

AVALIAÇÃO DA EFICÁCIA DA MANIPULAÇÃO DE IMAGENS RADIOGRÁFICAS OCLUSAIS DIGITALIZADAS SUB E SUPEREXPOSTAS

RESUMO

O objetivo do presente estudo foi verificar a possibilidade de se manipular imagens radiográficas digitalizadas sub e super-expostas e fazer com que as mesmas apresentem boa qualidade para interpretação e elaboração do diagnóstico radiográfico. Foram feitas 13 radiografias intrabucais oclusais totais da maxila em um crânio seco submetido a 13 diferentes tempos de exposição. As radiografias foram digitalizadas e posteriormente manipuladas em programa de edição de imagens. Foram realizadas 143 avaliações por especialistas em radiologia odontológica que classificaram as imagens em adequadas ou não para interpretação. Os resultados mostraram que as imagens sub-expostas quando manipuladas foram consideradas adequadas para interpretação e elaboração de diagnóstico, o que não ocorreu com as imagens super-expostas. Sendo assim, concluiu-se que é possível manipular imagens radiográficas digitalizadas com 75% de redução do tempo de exposição ideal e fazer com que as mesmas apresentem qualidade adequada para interpretação. No entanto, concluiu-se que imagens super-expostas a partir de 57,50% acima do tempo de exposição padrão ficaram inadequadas para interpretação e elaboração do diagnóstico.

Palavras chave: intensificação de imagem radiográfica, processamento de imagem assistida por computador, radiografia dentária.

INTRODUCTION

Radiographic examination is a complementary and essential diagnostic tool in dentistry. Murapu and Singer[1] claimed that no tool in dentistry is more vital for diagnosis or therapeutic planning than radiography. One of the most useful radiographic techniques is the occlusal intraoral technique, developed by Simpsom in 1916, and can often be used as a complementary exam in periapical radiography, because it allows the observation of extensive areas[2].

Due to the importance of this technique, research in this area is necessary. Similar studies[3-9] have used the periapical or bitewing techniques. Few studies, however, have investigated, simultaneously, the effect of sub and over-exposures[7].

The quality of the radiographic image is essential to guarantee diagnostic accuracy. However, some factors such as exposure time and development of the films are easily modified in clinical practice, often yielding low density or over-dark images that are difficult to visualize. Nowadays, the conventional radiograph can profit from computerized resources for image capture with appropriate scanners[3,5,9,10]. The main advantage of this resource is the possibility to manipulate the image in terms of brightness and contrast enhancement, linear and angular dimensions,

contour edge's enhancement, color application, image inversion, determination of the optic density (expressed as the mean value of shades of grey corresponding to the pixels in the selected area), attach comments, let in third dimension, correct sub or over-exposure, and show graphs which depict the distribution of the shades of grey. Moreover, the reduction in x-ray dose given to the patients is also mentioned as an advantage of this system[8].

With the improvement of the manipulation resources for digital and digitized images, research is necessary to establish limits to improve the accuracy of diagnosis. However, the indiscriminate use of these resources must be avoided.

Therefore, the aim of this study was to evaluate whether it is possible to manipulate digitized occlusal radiographic images, dealing with sub and over-exposures to guarantee that the quality of the images will be suitable for diagnosis.

MATERIAL AND METHODS

The radiographic images were obtained employing a dry skull of the Division of Dental Radiology of São José dos Campos Dental School. A 1.8-cm-thick acrylic attenuator was placed between the collimator and the object to simulate the radiation scattering effect of soft tissues. This method was used by Mol and Dunn[11].

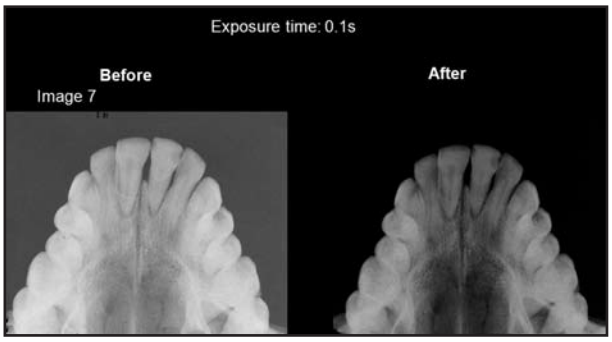

Fig. 1: Sub exposure radiograph before and after image treatment.

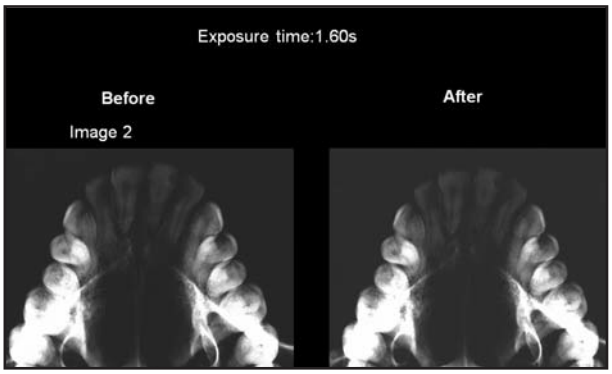

Fig. 2: Over-exposure radiograph before and after image treatment.

The skull was radiographed employing the cross-sectional maxillary occusal projection. The skull was placed on a flat bench, in such a way that the sagittal plane was perpendicular to the floor and the occlusal plane was horizontal. Utility wax was placed at the base of the skull to fix the position. Thirteen Kodak Insight 57 mm x 76 mm films (Rochester, New York) were employed. The long dimension was placed perpendicular to the sagittal plane in agreement with principles reported by White and Pharoah[2].

A gendex 765 DC x-ray generator was used at 65kVp, 7mA.

The standard radiograph was established by experts in dental radiology before image manipulation. These professionals compared the images obtained with exposures times between 0.2s and 0.5s and chose the radiograph obtained with an exposure time of 0.4s as the standard. Detail visualization was maximum in this radiograph and density and contrast were average. Based on this standard exposure time, 6 sub-exposure times (0.32s, 0.25s, 0.20s, 0.16s, 0.125s and 0.1s) and six over-exposure times (0.5s, 0.63s, 0.8s, 1.0s, 1.25s and 1.60s) were established. These times were determined in accordance with the equipment Gendex 765 DC. The longest exposure time (1.6s) used was 4 times above the standard time (0.4s) and the minimum time (0.15s) was 4 times shorter then the standard time.

The radiograph was digitized with the scanner EPSON Perfection 4990 Photo (*Epson America Inc., Long Beach, California, USA*) with the transparency scanning option and its respective software SilverFast® SE 6. The digitalization was performed at a resolution of 300 dpi and the images were saved as TIFF (*Tagged Image File Format*).

The manipulation was carried out by one of the authors with experience in image manipulation programs. The tools of image, set up, brightness and contrast of the images edition program Adobe Photoshop CS version 8.0.1 were employed. Only the radiographs obtained with the exposure time of 0.4 seconds (standard) were not manipulated. The figures 1 and 2 show radiographs obtained by sub and over-exposure before and after manipulation.

Table 1: Image number corresponding to each exposure time

Radiographic images	Exposure time
7	0.100s
12	0.125s
10	0.160s
5	0.200s
1	0.250s
8	0.3200s
4	0.400s
9	0.500s
6	0.630s*
13	0.800s*
3	1.000s*
11	1.250s*
2	1.600s*

* statistically significant at 5% level

Table 2: Statistical analysis (Z test) and the percentage of the examiners' answers

Variable	Z	P	% (not)
Image 1	0.30	0.763	9.09
Image 2	3.32	0.001*	100
Image 3	2.11	0.035*	63.64
Image 4	0.30	0.763	9.09
Image 5	0.00	1.000	0
Image 6	2.71	0.007*	81.82
Image 7	1.51	0.132	45.45
Image 8	0.60	0.546	18.18
Image 9	0.90	0.366	27.27
Image 10	0.30	0.763	9.09
Image 11	3.32	0.001*	100
Image 12	0.60	0.546	18.18
Image 13	3.32	0.001*	100

* statistically significant at 5% level

The radiographs were numbered at random and the examiners were blind to the exposure time corresponding to each image.

The monitor used (14.0" WXGA High-Definition Bright View Widescreen (1280 x 768) Display) was the same for all the evaluations. Dim lighting was employed to avoid interfering with image evaluation.

Thirteen sets of radiographs were evaluated by 11 specialists in dental radiology in a total of 143 exams. The specialists analyzed the images, individually, assigning a score of 1 when the image was suitable for interpretation and diagnosis and 2 when the radiograph was not suitable for diagnosis. Graphs and tables were constructed to show the adequacy of image quality for diagnosis for each of the exposure times. Statistical analysis of the data was performed with test Z.



Fig.3: Graphical representation of the examiner answers in 5% level of significance.

RESULTS

Table 1 shows the image number corresponding to each exposure time. The time of 0.4s was considered standard.

The Z test was employed to check the examiner's answers at 5% level of significance and yielded the following results (Figure 3).

The hatch columns in this graph represent the answers of the examiners with a statistically difference at 5% level of significance.

When the quality of the digitized and improved images was evaluated to determine whether they were suitable or not for interpretation and diagnosis, two distinct sets of results were obtained for the sub-exposure and over-exposure groups. In the cases of sub-exposure, the images exhibited a value of $p \geq 0.132$. The over-exposure group of images, 0.63s (p=0.007); 0.8s (p=0.001); 1.0s (p=0.035); 1.25s (p=0.001); and 1.6s (p=0.001), were considered unsuitable even after file manipulation using the tools of brightness, contrast and sharpness.

Table 2 shows the statistical analysis (Z test) and the percentage of the examiners' answers.

Figure 4 shows a radiograph obtained with an exposure time of 0.2 seconds (image 5), before and after image treatment, P=1.000 indicating better image interpretation according to the examiners.

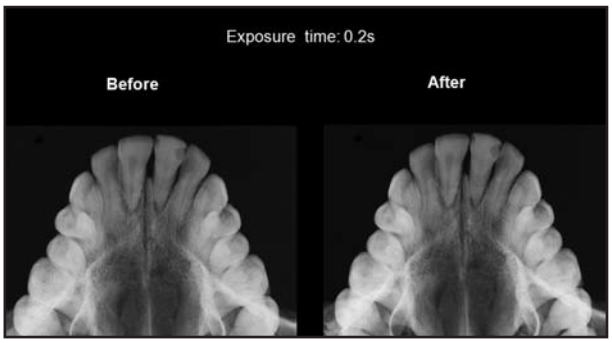

Fig. 4: Radiograph obtained with 0.2 seconds exposure, before and after image treatment.

DISCUSSION

Since the end of the 70's, when some of the devices for image capture were created, it became possible to manipulate, store, restore and change radiographic information using the digitized images. The advantages of digitized radiographic images are incontestable, as reported by many studies[3,5,10,12], and revealed by their widespread use in dental practice nowadays. However, it is necessary to verify alteration limits for physical factors such as the exposure time. These factors influence the image quality that in turn guarantees the acquisition of a satisfactory image for radiographic diagnosis.

The occlusal radiographic technique was chosen to obtain a larger examination area. Physical features of the patient such as biotype, age, and anatomy can influence the ideal exposure time[2,3]. Therefore, to exclude these variations, we used a single object for analysis.

Subjective analysis was chosen for being closer to clinical dental practice than the quantitative analysis in accordance with Oliveira et al.[13]

The scanning settings and film position were carefully selected and standardized before each scan in agreement with Chen e Hollender[10].

In the present study, we used the TIFF format for image storage; 300 dpi of resolution and 8 bits were selected based on the results of other studies[3, 5, 7, 14, 15]. Although the Adobe Photoshop 8.0 program is not specifically tailored for processing radiographic images, it has the necessary resources and was very useful for image manipulation. Similar tools (brightness and contrast) in other image edition programs were used in a similar way by different investigators[4,8,9,10].

The quality of the manipulation process can be confirmed by the results of the image obtained with exposure 0.2s (image 5). Following manipulation, this image was considered suitable for diagnosis by 100% of the researchers. The standard radiograph was not subjected to manipulation. These results can be considered beneficial because they imply that the individuals may be exposed to lower doses of radiation without deteriorating diagnostic efficacy, given that the sub exposure can be corrected digitally. Furthermore, the results obtained in this study suggest that the professional can predict how the conventional radiographs obtained with inadequate exposure times or defective processing can be improved without the need to re-expose the patient to X- rays.

In the present study, radiographs obtained with low exposure showed lack of contrast, prior to manipulation, when compared to exposure time of 0.4 seconds (standard). However, we conclude that images obtained by sub-exposure (up to 75% of the standard time) can be manipulated to render them adequate for diagnosis (Table 1). In a similar study, Kerbaury[8] obtained radiographs by sub exposure only and concluded that a 60% reduction in the time of exposure can still yield radiographic image quality suitable for diagnosis in approximately 80% of the images after treatment. However, the method for scanning of the images used by this author was composed of a system of digital image camera attached to the controller and the microcomputer software and had fewer resources than the one used in this study. The use of an appropriate scanner and updated software may have contributed to rendering sub-exposed radiographic images adequate for diagnosis in terms of density and contrast.

This explanation is based on the study of Attaelmanan et al.[16] in which the authors report that the use of high resolution optical scanners can avoid the use of interpolated resolutions which would impair the quality of the final image.

Authors of other studies[7,12] showed that although over-exposed radiographs result in a greater proportion of accurate diagnosis, they are also responsible for a greater number of false positives. In these studies, the radiographs were obtained with exposure times that were 2.5 times longer than the middle time of 0.45 seconds but proved unsuitable for diagnosis.

Sarmento[17] suggests excessive exposure times tend to reduce the quality of the image. The present over-exposure data confirm this statement. When the

radiograph is obtained with an exposure time 57.50% in excess of the ideal time of exposure, the manipulation of the scanned image is not enough to make it suitable for diagnosis.

The present data allow us to conclude that it is preferable to use sub-optimum exposure times. None of the sub-exposed images proved inadequate for interpretation.

The present study involved the assessment of image quality by trained professionals, i.e. subjective evaluation. Further studies are warranted to validate subjective analysis employing quantitative evaluation.

CORRESPONDENCE
Patrícia Superbi Lemos Maschtakow
Faculdade de Odontologia do Campus
de São José dos Campos – UNESP
Departamento de Diagnóstico e Cirurgia -
Disciplina de Radiologia Odontológica.
Avenida Eng. Francisco José Longo, 777
Bairro: Jardim São Dimas
São José dos Campos-SP Cep: 12245-000 - Brasil
e-mail: pat.lemos@yahoo.com.br

REFERENCES

1. Mupparapu M, Singer SR. Implant imaging for the dentist. J Can Dent Assoc 2004;70:32.
2. White SC, Pharoah MJ. Exames Radiográficos Intra-Orais. In: White SC, Pharoah MJ. Radiologia Oral: Fundamentos e Interpretação. Rio de Janeiro: 2000; Elsevier; p. 123-167.
3. Janhom A, Ginkel FC, JP A, Amerongen JP, Stelt. Scanning resolution and the detection of proximal caries. Dentomaxillofac Radiol 2001;30:166-171.
4. Kerbaury WD. Digital image processing of periapical radiographs with low dose of radiation. [Dissertação]. São José dos Campos: São Paulo State University, p 93 São José dos Campos Dental School; 1995
5. Ohki M, Okano T, Nakamura T. Factors determining the diagnostic accuracy of digitized conventional intra oral radiographs. Dentomaxillofac Radiol 1994;23:77-82.
6. Sarmento VA, Pinho CB, Rivas CC. Influência do tempo de exposição à radiação X e do tamanho de captura da radiografia na amplitude dinâmica de imagens digitalizadas. Rev. Odontol. Unesp 2002;31:61-70.
7. Skodje F, Espelid I, Kvile K, Tveit AB. The influence of radiographic exposure factors on the diagnosis of occlusal caries. Dentomaxillofac Radiol 1998;27:75-79.
8. Wenzel A. Computer-aided image manipulation of intraoral radiographs to enhance diagnosis in dental practice: a review. Int Dent J 1993;43:99-108.
9. Fujita M, Kodera Y, Ogawa M, Wada T, Doi K. Digital image processing of periapical radiographs. Oral Surg. Oral Med Oral Pathol 1988;65:490-494.
10. Chen SK, Hollender L. Digitizing of radiographs with a flatbed scanner. J Dent 1995;23:205-208.
11. Mol A, Dunn SM. The performance of projective standardization for digital subtraction radiography. Oral Surg Oral Med Oral Pathol 2003;373-382.
12. Lavelle CLB, WU CJ. When will excellent radiographic images be available to the general dental office? Dentomaxillofac Radiol 1987;22:125-132.
13. Oliveira AE, Almeida SM de, Paganini GA, Haiter Neto F, Bóscolo FN. Comparative study of two digital radiographic storage phosphor systems. Braz Dent J 2000;11:111-116.
14. Güidal P, Hidbolt CF, Akdeniz BG. The effects of different image file formats and image-analysis software programs on dental radiometric digital evaluations. Dentomaxillofac Radiol 2001;30:50-55.
15. Sarmento VA, Pretto SM, Costa NP. Entendendo a imagem digitalizada. Revista Odonto Ciência 1999;27:171-179.
16. Attaelmanan A, Borg E, Gröndhal H G. Digitisation and display of intra-oral films. Dentomaxillofac Radiol 2000;29:97-102.