

## BONE SUBSTITUTE IN THE REPAIR OF THE POST-EXTRACTION ALVEOLUS

Sebastián Fontana<sup>1</sup>, Luis M. Plavnik<sup>1</sup>, Sandra J. Renou<sup>2</sup>, Marta E. González de Crosa<sup>3</sup>

<sup>1</sup> Department of Histology & Embriology ("A"). School of Dentistry, National University of Córdoba, Argentina.

<sup>2</sup> Department of Oral Pathology, School of Dentistry, University of Buenos Aires, Argentina.

<sup>3</sup> Scientific & Technologic area of the "CREO Foundation". Córdoba, Argentina.

### ABSTRACT

*In recent years there has been increasing interest in the choice of the best material for bone substitutes. Experimental models enable estimation of biological potential, efficacy and safety of a biomaterial before its clinical application. The aim of this study was to evaluate the response of a bone substitute, UNC bone matrix powder (MOeP-UNC), for repairing the post-extraction alveolus in Wistar rats. Rats' first lower molars were extracted. The right alveoli were filled with MOeP-UNC hydrated with physiological saline (Experimental Group, EG), and the left alveoli were used as Control Group (CG).*

*Thirty days after extraction, the animals were killed and the samples processed. Histological sections were made in vestibular-*

*lar-lingual direction at the level of the mesial alveolus of the first inferior molar (Guglielmotti et al. J. Oral Maxillofac. Surg. 1985;43(5):359-364). Repair of the alveoli at 30 days after extraction was evaluated histologically.*

*Repair of the alveolus was optimum in the control group at 30 days, and the EG showed presence of MOeP-UNC particles in close contact with newly formed bone tissue (osseointegration). In the experimental model used, at 30 days post-surgery, the MOeP-UNC particles integrate compatibly with newly formed bone tissue.*

*Key words: bone healing, osteoinduction, osteogenesis, freeze dried bone.*

## SUBSTITUTO ÓSEO EN LA REPARACIÓN DE ALVÉOLOS POST-EXTRACCIÓN

### RESUMEN

*En los últimos años se ha incrementado el interés por la elección del material más adecuado como sustituto óseo. Los modelos experimentales permiten estimar el potencial biológico, la eficacia y seguridad de un biomaterial, previo a su aplicación clínica. El objetivo del presente estudio fue evaluar la respuesta de un sustituto óseo, matriz ósea-UNC en polvo (MOeP-UNC), en la reparación alveolar post-exodoncia en ratas Wistar. Se realizó la exodoncia de los primeros molares inferiores. En los alvéolos derechos se colocó MOeP-UNC hidratada con solución fisiológica (Grupo Experimental, GE). Los alvéolos izquierdos, fueron utilizados como Grupo Control (GC).*

*A los 30 días post-exodoncia los animales fueron sacrificados y las muestras obtenidas se procesaron, se realizaron cortes*

*histológicos en sentido vestibulo-lingual a la altura del alvéolo mesial del primer molar inferior (Guglielmotti et al. J Oral Maxillofac Surg. 1985;43(5):359-364). Se realizó la evaluación histológica de la reparación de los alvéolos a los 30 días post cirugía. El grupo control presentó una óptima reparación alveolar a los 30 días y en el GE se evidenció la presencia de las partículas de MOeP-UNC en íntimo contacto con el tejido óseo neoformado (oseointegración). En el modelo experimental utilizado, a los 30 días post-cirugía las partículas MOeP-UNC se integran de manera compatible con el tejido óseo neoformado.*

*Palabras clave: cicatrización ósea- osteoinducción-osteogénesis- hueso desecado y congelado.*

### INTRODUCTION

In recent years there has been increasing interest in the choice of the best material for substitutes used for repairing bone defects.

The main aims of a biomaterial for bone tissue are that it should: a) restore form and function, b) significantly shorten the physiological process of ossification and c) be easy to manipulate<sup>1</sup>.

Some of the alternatives for bone substitutes are the following:

**Autologous or autogenous grafts** are taken from the patient him/herself and may be harvested from different intra-oral donor sites (chin, maxillary tuberosity, ascending branch) or extra-oral donor sites (iliac crest, tibia, calvaria). This is the material of choice because of its high osteogenic capacity and low antigenicity, e.g. autologous bone.

**Homologous or allogeneic grafts, or allografts** come from individuals of the same species, but who are

genetically different. The types most often used are freeze dried bone allograft (FDBA) and demineralized freeze dried bone allograft (DFDBA), also called demineralized bone matrix.

**Heterologous grafts or xenografts** come from an animal of a different species, eg deproteinized bovine bone mineral (Bio-Oss, Giestlich Pharma).

**Alloplastic or synthetic grafts** are synthetically manufactured materials<sup>2</sup>. Among the most often used of these materials are bioactive glass (Bio-glass) and tricalcium phosphate (TCP)<sup>2</sup>.

The new bone that will form in a bone defect treated with particulate grafts is mediated by processes of osteogenesis, osteoconduction and/or osteoinduction. These processes could take place individually or simultaneously, depending on the nature of the material used<sup>3-6</sup>.

According to the literature, the ideal filling material is autologous bone graft, since there is the possibility to retain cell viability, graft revascularization and there is no possibility of disease transmission<sup>1,7-9</sup>. However, obtaining an autologous bone graft requires a surgical procedure at the donor site, with the consequent risk of postoperative morbidity (infection, pain, hemorrhage, muscular weakness and neurological injury, among others). Surgical time also increases considerably; and in some cases the amount of graft harvested may be insufficient<sup>10,11</sup>. Thus, the use of alternative filling materials has increased. Biomedical publications<sup>1,6,7</sup> reflect the search for an ideal substitute for autologous bone, nevertheless, there is some controversy regarding methodology and interpretation of the results<sup>7,11,12</sup>.

The aim of this study is to evaluate the response of a bone substitute, UNC bone matrix powder (MOeP-UNC), for repair of the post-extraction alveolus in Wistar rats.

## MATERIALS AND METHODS

### Filling Material

UNC bone matrix powder (MOeP-UNC) is human bone tissue from the Bone Bank at Córdoba Hospital (Córdoba, Argentina), which meets the requirements established by Argentina's National Institute for Organ Donation and Transplantation (*Instituto Nacional Central Único Coordinador de Ablación e Implante*, INCUCAI). Bone from a single donor is processed, lyophilized and sterilized by gamma radiation.

The Human Tissue Processing Plant of the Blood Derivative Laboratory at Córdoba National University is authorized by INCUCAI and the National Medication, Food and Medical Technology Administration (*Administración Nacional de Medicamentos Alimentos y Tecnología Médica*, ANMAT). The UNC Bone Matrix is registered as Medical Technology (ANMAT) under medical product register number 1007-1/2).

### Histomorphometric Measurement of Particles

Sixty bone substitutes particles were measured using image analysis software (Image Pro-Plus 4.5) to determine their equivalent diameter. Equivalent diameter is obtained by considering the irregular area of the particle under observation to be a perfect circle<sup>13</sup> (Fig. 1).

### Surgical Procedure

Sixteen male Wistar rats weighing 80 g ( $\pm 10$  g) were anesthetized with Ketamine solution (8 mg/100 g body weight; Ketamina Zoovet, Lab. Zoovet, Argentine) and Xilazine (1.28 mg/100 g body weight; Sedomin, Lab Konig, Argentine).

The methodology described by Guglielmotti MB et al.<sup>14</sup> was followed for the extractions. In order to achieve the approach and perform surgical procedures in the rat buccal cavity, a special examination table was designed to keep the animals in dorsal decubitus position with the mouth held open by means of a system of fasteners. The first lower molars were extracted using instruments that were proportional to the size and shape of the teeth. After extraction, the right alveoli were filled with MOeP-UNC hydrated with physiological saline (Expe-

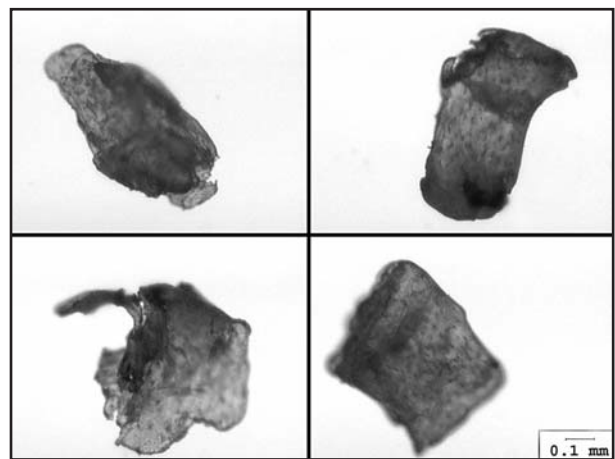


Fig. 1: Macroscopic appearance of MOeP-UNC bone substitute (Original Magnification x 45).

rimental Group, EG) and the left alveoli were left unfilled (Control Group, CG).

NIH standards for the use and care of laboratory animals were followed (NIH publication N° 85-23, revised 1985). The experimental protocol was approved by the Committee of Bioethics of the School of Medical Science at Córdoba National University. Thirty days after the extraction the rats were killed, and the hemimaxillaries were dried, radiographed, demineralized and embedded in paraffin. Vestibulo-lingual sections were made at the level of the mesial alveolus of the first inferior molar for histological study.

A descriptive analysis was made of the presence of MOeP particles implanted in the alveoli after extraction and newly formed bone tissue directly related to them (osseointegration).

## RESULTS

### *Histomorphometric Analysis*

The image analysis software determined that the equivalent diameter of the particles was  $535.42 \mu\text{m}$  ( $\pm 233.90$ ), ranging from  $125.85 \mu\text{m}$  to  $1069.86 \mu\text{m}$ . (Fig. 2).

### *Histological Analysis*

Thirty days post-extraction, the alveolus in the control group was completely filled with lamellar bone. In all the experimental cases, the MOeP-UNC particles were found to be surrounded by newly formed bone (osseointegration). Osteocytic cells in their lacunae, peripheral osteoblasts and presence of osteoid matrix were found in the newly formed bone tissue (Figs. 3, 4 and 5).

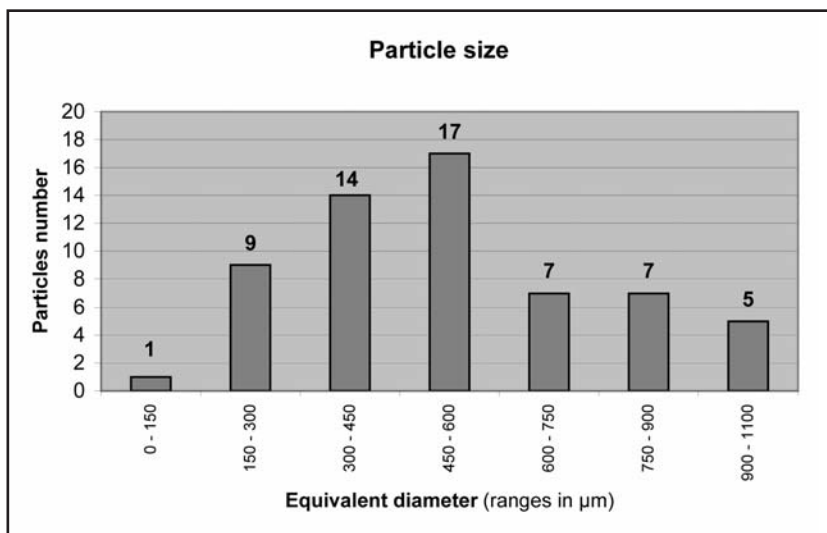


Fig. 2: Particle size in UNC bone matrix powder (n: 60).

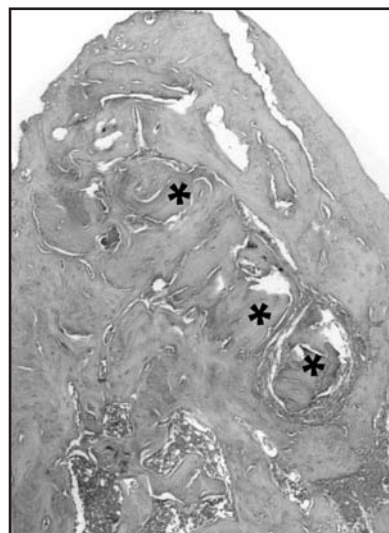


Fig. 3: Bone particles (\*) in alveolus 30 days after extraction. (H/E - Original Magnification x 45).

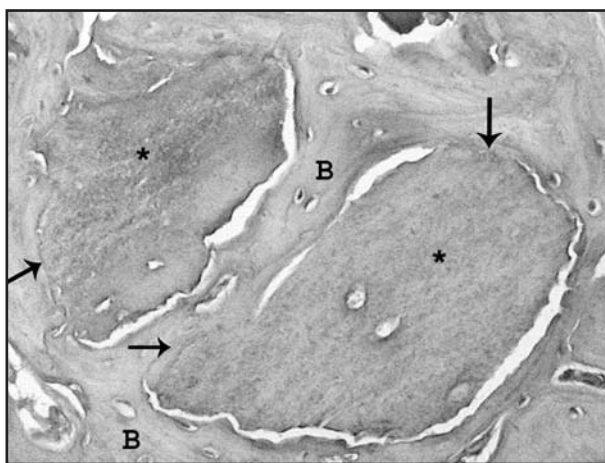


Fig. 4: Newly formed bone tissue (B) in direct relation ( $\uparrow$ ) to the bone substitute (\*). (H/E Original Magnification x 100).

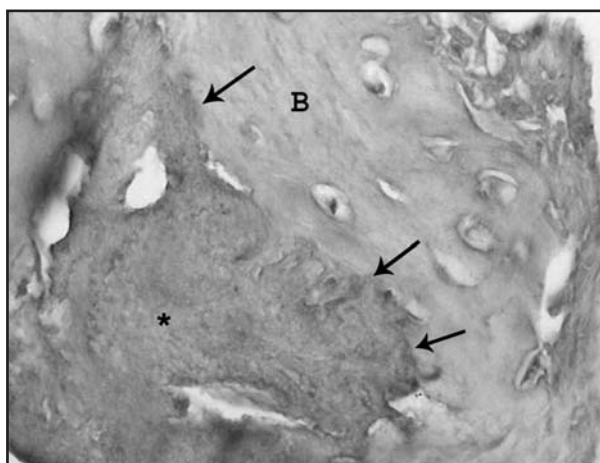


Fig. 5: Bone particle (\*) and newly formed bone tissue (B) closely related to its surface ( $\uparrow$ ). (H-E Original Magnification x 400).

The presence of filler material did not interfere with repair of the post-extraction alveolus in this experimental model. During the study time (30 days) the MOeP-UNC particles integrated compatibly with the newly formed bone tissue.

## DISCUSSION

Autologous bone is considered to be the gold standard for bone substitution, but some disadvantages have been reported, as mentioned above<sup>10,11</sup>. Ochandiano Caicoya suggests that the cells in this type of graft die when they are more than 100 mm away from a vascular source (it is estimated that 95% of the graft osteoblasts undergo necrosis)<sup>12</sup>. Under these circumstances, the advantages of this type of filling would be lost and it would behave as a non-living graft. Regarding allografts, those of human origin are most often used, such as freeze-dried bone allograft (FDBA), which was the first to be used, and Demineralized Bone Matrix (DFDBA), which was described by Urist, showing that its extra-skeletal implantation in experimental animals resulted in heterotopic ossification by means of an osteoinductive mechanism<sup>15</sup>.

To date, clinical and experimental studies do not agree on whether FDBA or DFDBA-based fillings trigger osteoinduction and/or osteoconduction processes, probably due to controversies regarding methodology and interpretation of results, which are systematically repeated in the literature<sup>8,16</sup>.

In this regard, the post-extraction repair of the alveolus model in rats<sup>14</sup> was selected for our study with the aim of obtaining transferable results on biocompatibility and osteoconduction of MOeP-UNC. The results showed that the implanted particles did not interfere with post-extraction repair of the alveolus in rats and that over the study period (30 days) the MOeP-UNC particles inte-

grated compatibly with the newly formed bone tissue (osteoconduction).

These results agree with those of Glowacki<sup>17</sup>, who states that if non-critical bone defects are filled with biomaterials (e.g., in the case of post-extraction alveoli where only the crest wall is missing), only osteocompatibility and osteoconductivity are being demonstrated, but not osteoinduction.

Although it has been proposed by means of different experimental models that demineralized bone particles (DFDBA) have an osteoinductive effect<sup>15,18</sup>, other studies have questioned the benefits of this type of filling<sup>19,20</sup>. A possible cause of this variability in the results may be that the age of bone donors was not considered in tissue banks<sup>20</sup>. It is also very important to monitor closely all the steps required for demineralization and sterilization (whether with ethylene oxide, high temperatures or gamma radiation) because they might reduce bone induction by up to 40%<sup>21</sup> or cause protein denaturation and/or inactivation, particularly of BMP, which is determinant in osteoinduction<sup>22,23</sup>.

Particle size seems to be another key variable regarding the success of bone substitutes used as fillers<sup>24</sup>, which is the reason why this study measured MOeP-UNC particle size using Image Pro-Plus 4.5 image analysis software. Mean diameter was found to be 535.42  $\mu\text{m}$ . These data place MOeP-UNC particles within parameters described in previous studies, which suggest that particles ranging from 125 to 1000  $\mu\text{m}$  produce greater osteogenic effect than those smaller than 125  $\mu\text{m}$  or larger than 1000  $\mu\text{m}$ <sup>18,24</sup>.

We therefore recommend the use of MOeP-UNC particles for bone fillings, since, in contrast to autografts, they do not require a donor site for harvesting; they have high mineral content, providing better physical properties than DFDBA particles, and they trigger osteoconductive effects.

## ACKNOWLEDGMENTS

We are grateful to UNC Biotecnia, Blood Derivative Laboratory at Córdoba National University, for providing Bone Matrix Powder (MOeP-UNC).

This Project was approved by the Secretariat of Science and Technology at Córdoba National University (SeCyT, UNC - N°: 05-J060).

## REFERENCES

1. Al Ruhaimi KA. Bone grafts substitutes: a comparative qualitative histologic review of current osteoconductive materials. *Int J Oral Maxillofac Implants* 2001;16(1):105-114.

## CORRESPONDING AUTHOR

Dr. Sebastián Fontana

Boulevard Chacabuco 770, 2° P

CP 5000; Córdoba Argentina.

e-mail: sfontana@odo.unc.edu.ar

2. Infante Cossio P, Gutierrez Perez JL, Torres Lagares D, García P, González Padilla JD. Bone cavity augmentation in maxillofacial surgery using autologous material. *Rev Esp Cirug Oral y Maxilofac* 2007;29(1):7-19.



3. Marx RE, Carlson ER, Eichstaedt RM, et. al. Platelet-rich plasma. Growth factor enhancement for bone grafts. *Oral Surg Oral Med Oral Pathol Oral Radiol Endod* 1998;85: 638-646.
4. Anitua E. Plasma rich in growth factors: preliminary results of use in the preparation of future sites for implants. *Int J Oral Maxillofac Implants* 1999;14(4):529-535.
5. Fontana S, Olmedo DG, Linares JA, Guglielmotti MB, Crosa ME. Effect of platelet-rich plasma on the peri-implant bone response: an experimental study. *Implant Dent* 2004; 13(1):73-78.
6. Cooper LF. Biologic determinants of bone formation for osseointegration: clues for future clinical improvements. *J Prosthet Dent* 1998;80(4):439-449.
7. Becker W, Becker BE, Caffesse R. A comparison of demineralized freeze-dried bone and autologous bone to induce bone formation in human extraction sockets. *J Periodontol* 1994;65(12):1128-1133.
8. Schwartz Z, Mellonig JT, Carnes DL y col. Ability of commercial demineralized freeze-dried bone allograft to induce new bone formation. *J Periodontol* 1996;67(9):918-926.
9. Venturelli A. Regeneración Osea: Plasma Rico en Plaquetas. *Rev Asoc Odontol Argent* 1999;87(6):459-467.
10. Güllaldi NC, Shahlafar J, Makhsoosi M, Caner B, Araz K, Erben G. Scintigraphic evaluation of healing response after heterograft usage for alveolar extraction cavity. *Oral Surg Oral Med Oral Pathol Oral Radiol Endod.* 1998 May; 85(5):520-525.
11. Stevenson S. Biology of bone graft. *Orthop Clin North Am.* 1999;30:543-552.
12. Ochandiano Caicoya S. Bone cavity filling with alloplastic material in maxillofacial surgery. *Rev Esp Cirug Oral y Maxilofac* 2007;29(1):21-32.
13. Ingram JH, Kowalski R, Fisher J, Ingham E. The osteolytic response of macrophages to challenge with particles of Simplex P, Endurance, Palacos R, and Vertebroplastic bone cement particles in vitro. *J Biomed Mater Res B Appl Biomater.* 2005 Oct;75(1):210-220.
14. Guglielmotti MB, Cabrini RL. Alveolar wound healing and ridge remodeling after tooth extraction in the rat: a histologic, radiographic, and histometric study. *J Oral Maxillofac Surg.* 1985;43(5):359-364.
15. Urist MR. Bone: formation by autoinduction. *Clin Orthop Relat Res.* 2002 Feb;(395):4-10.
16. Piattelli A, Scarano A, Corigliano M, Piattelli M. Comparison of regeneration with the use of mineralized and demineralized freeze dried bone allografts: A histological and histochemical study in man. *Biomaterials* 1996;17(11): 1127-1131.
17. Glowacki J. A review of osteoinductive testing methods and sterilization processes for demineralized bone. *Cell Tissue Bank* 2005;6(1):3-12.
18. Guglielmotti MB, Alonso ME, Itoiz ME, Cabrini RL. Increased osteogenesis in alveolar wound healing elicited by demineralized bone powder. *J Oral Maxillofac Surg* 1990;48:487-490.
19. Laurell L, Gottlow J, Zybutz M, Persson R. Treatment of intrabony defects by different surgical procedures. A literature review. *J Periodontology* 1998;69:303-313.
20. Schwartz Z, Somers A, Mellonig JT y col. Ability of commercial demineralized freeze-dried bone allograft to induce new bone formation is dependent on donor age but not gender. *J Periodontol* 1998;69(4):470-478.
21. Zhang Q, Cornu O, Delloye C. Ethylene oxide does not extinguish the osteoinductive capacity of demineralized bone. A reappraisal in rats. *Acta Orthop Scand* 1997;68(2):104-108.
22. Shigeyama Y, D'Errico JA, Stone R, Somerman MJ. Commercially-prepared allograft material has biological activity in vitro. *J Periodontol* 1995;66(6):478-487.
23. Becker W, Urist MR, Trucker LM, Becker BE, Ochsenbein C. Human demineralized freeze-dried bone: inadequate induced bone formation in athymic mice. A preliminary report. *J Periodontol* 1995;66(9):822-828.
24. Shapoff CA, Bowers GM, Levy B, Mellonig JT, Yukna RA. The effect of particle size on the osteogenic activity of composite grafts of allogeneic freeze-dried bone and autogenous marrow. *J Periodontol* 1980;51(11):625-630.