

## DURATION OF THE PEAK OF ADOLESCENT GROWTH SPURT IN CLASS I AND II MALOCCLUSION SUBJECTS USING A CERVICAL VERTEBRAE MATURATION ANALYSIS

Rodrigo Salazar-Lazo<sup>1</sup>, Luis E. Arriola-Guillén<sup>2</sup>, Carlos Flores-Mir<sup>3</sup>

<sup>1</sup> School of Dentistry, University of Applied Sciences, Lima, Peru.

<sup>2</sup> School of Dentistry, Científica del Sur University and University of San Marcos, Lima, Peru.

<sup>3</sup> Faculty of Medicine and Dentistry, University of Alberta, Edmonton, Alberta, Canada.

### ABSTRACT

The aim of the present work was to determine the duration of the adolescent peak growth spurt using cervical vertebral maturation analysis in class I and II malocclusion subjects.

The study was conducted on a sample which consisted of 154 lateral cephalograms of children and adolescents aged 9-15 years (84 females and 70 males). The evaluation of skeletal maturation stage was performed using a visual morphological analysis of CS3 and CS4 cervical vertebrae. The sagittal skeletal relation was evaluated according to Steiner analysis. Descriptive statistics were used to summarize chronological age in each malocclusion group and for each CS3 and CS4 skeletal maturation stage. Due to a lack of normal distribution,

comparisons of CS3 and CS4 age intervals on class I and II subjects were compared using the Mann-Whitney U test for independent samples.

The results show that the mean duration of the adolescent peak growth spurt was 10 months between CS3 and CS4 stages in class I malocclusion subjects, whereas in class II malocclusion patients the duration was 6 months. This difference of 4 months was statistically significant ( $p < 0.001$ ).

Finally, a clinically significant difference of 4 months in the duration of the adolescent peak growth spurt for class I and II malocclusion subjects was identified.

**Key words:** cervical vertebrae; cephalometry; malocclusion

## DURACIÓN DEL PICO DE CRECIMIENTO DE LA ADOLESCENCIA EN SUJETOS CON MALOCCLUSIÓN DE CLASE I Y II UTILIZANDO EL MÉTODO DE MADURACIÓN DE VÉRTEBRAS CERVICALES

### RESUMEN

El objetivo de la investigación fue determinar la duración del pico de crecimiento puberal a través del análisis de maduración de vértebras cervicales en adolescentes con maloclusión de Clase I y II.

La muestra de estudio estuvo constituida por 154 cefalogramas laterales de niños y adolescentes de 9-15 años de edad (84 mujeres y 70 hombres). Se realizó la evaluación de la etapa de maduración de las vértebras cervicales mediante el análisis morfológico visual (CS3 y CS4). Se evaluó la relación esquelética sagital de acuerdo al método de Steiner. Se realizó la estadística descriptiva para la edad cronológica en cada grupo de maloclusión y para cada etapa de maduración esquelética CS3 y CS4. Debido a la falta de distribución nor-

mal para las comparaciones de los intervalos de edad en CS3 y CS4 en sujetos de Clase I y II se utilizó la prueba de U de Mann-Whitney para muestras independientes.

Los resultados muestran que el promedio de duración del pico máximo de crecimiento puberal fue de 10 meses entre las etapas CS3 y CS4 en el grupo de maloclusión de Clase I, mientras que en el grupo de maloclusión de Clase II la duración fue de 6 meses. Esta diferencia de 4 meses fue estadísticamente significativa ( $p < 0.001$ ).

Finalmente se identificó una diferencia clínicamente significativa de 4 meses en la duración del período del pico de crecimiento puberal entre los adolescentes con maloclusión de Clase I y II.

**Palabras clave:** vértebras cervicales; cefalometría; maloclusión

### INTRODUCTION

Determination of craniofacial skeletal maturation and concomitant evaluation of its growth potential during preadolescence or adolescence is important for orthodontic treatment planning. One of the available diagnostic tools currently used is the evaluation of the morphological changes in the cervical vertebrae during skeletal maturation.<sup>1-3</sup> Growth potential and skeletal maturity can be determined

using anatomical changes of the cervical vertebrae observed on lateral cephalometric radiographs<sup>4</sup>. In 1972, Lamparski<sup>5</sup> created the first standards for cervical vertebral maturation as related to chronological age and to skeletal maturation through hand-wrist radiographs.

Baccetti *et al.*<sup>6,7</sup> presented an improved version of the cervical vertebral maturation (CVM) and its validity for the appraisal of mandibular skeletal

maturity. They related the vertical growth of the mandibular ramus (expressed cephalometrically by the measure Co-Go) to the morphology of the bodies of the second (C2 –odontoid process), third (C3), and fourth (C4) cervical vertebrae. Chen *et al.*<sup>8</sup> reinforced the possibility of evaluating mandibular growth with the use of cervical vertebral measurements based on the mandibular bone location next to the cervical vertebrae: the time of mandibular bone formation is closer to that of the cervical vertebral bone than of the hand-wrist bone. Subsequently, a few authors have warned that CVM has only a moderate level of correlation with the individual's skeletal maturation<sup>1-3</sup>, so calibration and training are prerequisites for correct diagnosis in research.

The Steiner cephalometric analysis is one of the tools that identify maxillary sagittal skeletal relations (anteroposterior discrepancy of the jaws). According to Steiner<sup>9</sup>, the relationship of the maxilla and mandible is defined by angle ANB. Class I occurs with an ANB angle of 0° to 4°; class II, with an ANB angle greater than 4°, and class III with an ANB angle below 0°. Although Steiner's ANB remains a reference for the sagittal skeletal relation diagnosis<sup>10-12</sup>, not all authors agree with it<sup>13,14</sup>, but in typical cases of Class II with great overjet, the diagnosis is more exact.

It has been reported that in subjects with Class III malocclusion, the greatest "increase" in mandibular length (coincident with the pubertal peak), occurred on average one year later in both sexes with Class III skeletal relationships than it did in those with Class I relationships<sup>15,16</sup>. The literature provides indications about the duration of the pubertal peak in subjects with Class I occlusions, and there is very little information for Class III<sup>15</sup>, but information about the duration of the growth peak in persons with Class II malocclusion is lacking and there is no comparative study comparing the length of the adolescent peak growth spurt between class I and II malocclusions. Significant differences have been found between class I and III malocclusions. Kuc-Michalska & Baccetti<sup>15</sup> reported greater increases in mandibular length during the pubertal peak for class III malocclusion subjects. They related this to a longer duration of the adolescent pubertal peak spurt than in subjects with normal sagittal skeletal relationship. Thus, the purpose of the study was to determine the duration of the

adolescent peak growth spurt according to Baccetti's cervical vertebral maturation analysis of skeletal Class I and II malocclusion subjects.

## MATERIALS AND METHODS

This study was approved by a local ethics committee. The pre-treatment lateral cephalograms of 154 subjects were analysed. The sample consisted of 84 males and 70 females, whose ages ranged from 9 to 15 years. They were divided into four groups according to their cervical vertebral maturation stages and skeletal facial growth pattern (CS3-Class I = 41, CS3-Class II = 43, CS4-Class I = 34, CS4-Class II = 36). Sample size was calculated considering the comparison of two means for sample size estimation with a one-sided significance level of 0.05, a standard deviation of 5 months, a precision of 6 months and a power of 90%. The expected variance was obtained from a pilot study based on the duration of the adolescent peak growth spurt in Class II between stages CS3 and CS4. Based on these parameters, a minimum of 18 patients per group was required, but the final number of patients per group was higher (Table 1).

The following inclusion criteria were considered:

- Lateral cephalograms of good quality.
- Skeletal Class I malocclusions (control group) included subjects with ANB  $2^\circ \pm 2^\circ$  according to Steiner,<sup>9</sup> bilateral Class I angle malocclusion, bilateral Class I molar relations, overjet 2 to 4 mm, and Frankfort to mandibular plane angle (FMA) within the range of  $25^\circ \pm 3^\circ$ .
- Skeletal Class II malocclusions based on the ANB  $>5^\circ$ , Class II-1 angle malocclusion, bilateral Class II molar relations, overjet greater than 5 mm, and Frankfort to mandibular plane (FMA) angle greater than  $29^\circ$ .

**Table 1: Sample distribution according to sex, skeletal relation and cervical vertebral stage.**

Skeletal relation	Cervical vertebral stage	Sex		
		Female	Male	Total
		n	n	n
Class I	CS3	21	20	41
Class I	CS4	20	14	34
Class II	CS3	23	20	43
Class II	CS4	20	16	36
		<b>84</b>	<b>70</b>	<b>154</b>

- Skeletal stages CS3 or CS4 based on the CVM method.<sup>7</sup> CS3 corresponds to the initial stage of the accelerative portion of the pubertal growth peak, and CS4 corresponds to the final stage of the accelerative portion of the pubertal growth peak in adolescents. (Figs. 1 - 5)

General exclusion criteria were patients with previous orthodontic treatment, with congenitally missing or extracted teeth or systematic diseases.

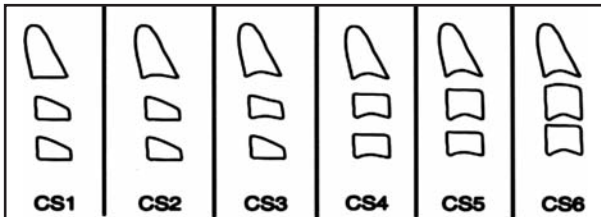


Fig. 1: Developmental stages of cervical vertebrae according to Baccetti's CVM method.

Imaging was performed with digital cephalometric panoramic equipment (ProMax<sup>®</sup>, Planmeca, Finland). Device settings were set at 16mA, 72 kV and 9.9 seconds. Cephalometric analyses were performed with Planmeca Romexis<sup>®</sup> software. ANB angle was determined and analysed for each patient. Patients were classified into 2 groups according to skeletal pattern: skeletal Class I ( $0^\circ \leq \text{ANB} < 4^\circ$ ) or Class II ( $\text{ANB} > 5^\circ$ ).

Cephalometric tracings were performed by a previously calibrated orthodontist, with 10 years' experience in drawing cephalograms. The intra- and inter-observer agreement was assessed with the kappa coefficient, which was 0.90 for osseous maturation and skeletal relation. All the cephalometric tracings were drawn twice, with a one-week interval between drawings.

Anatomical changes were observed in the concavity of the lower border of C3 and the bodies of C3 and

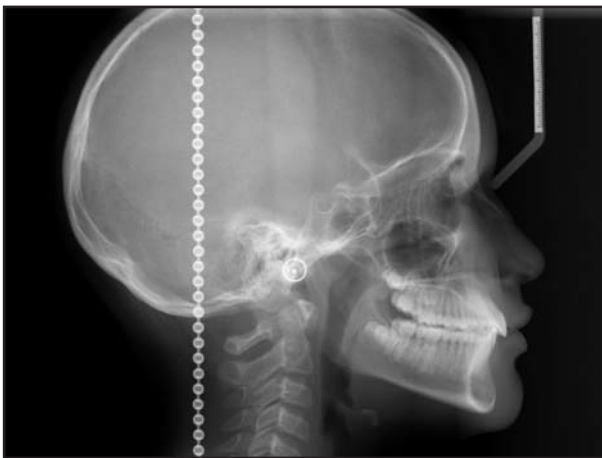

Fig. 2: Stage CS3 based on the CVM method in Class I.

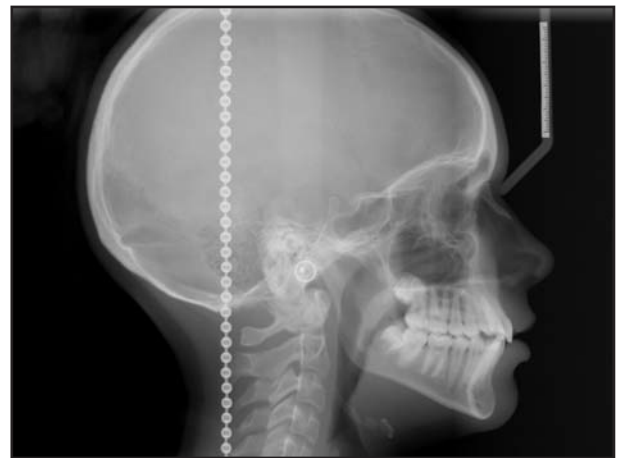


Fig. 3: Stage CS4 based on the CVM method in Class I.

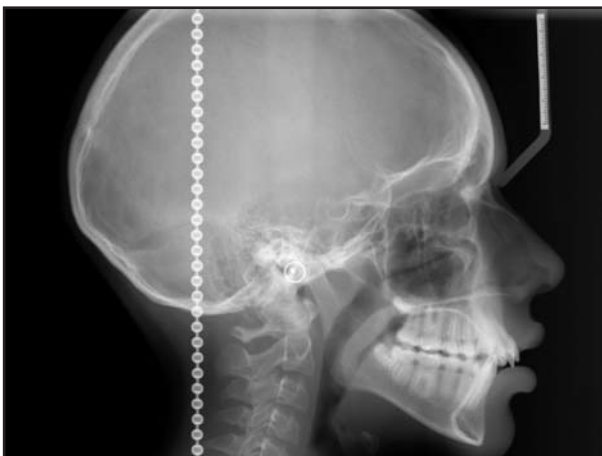

Fig. 4: Stage CS3 based on the CVM method in Class II.

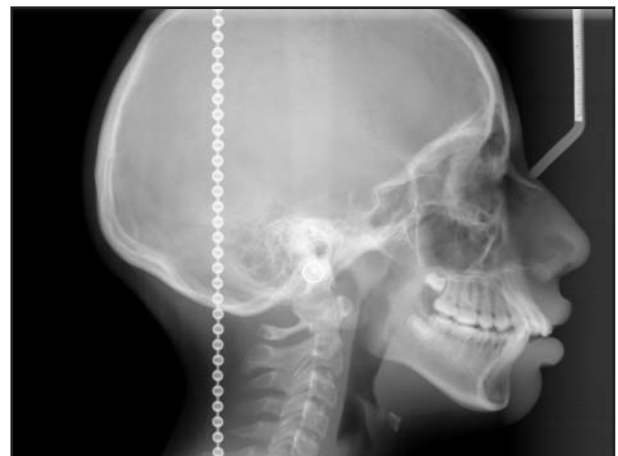


Fig. 5: Stage CS4 based on the CVM method in Class II.

C4 should be rectangular in stage CS3. For CS4, the concavity of the lower border of C3 and C4 was also observed and both were rectangular shaped <sup>7</sup>.

### Statistical Analysis

The collected data were statistically analyzed using SPSS ver.20 for Windows (IBM SPSS, Chicago, Illinois, USA). Descriptive statistics were used to summarize class I and class II malocclusion chronological age in each group and for each CS3 and CS4 skeletal maturation stages. Due to a lack of normal distribution, comparisons of CS3 and CS4 age intervals in class I and II malocclusion subjects were analyzed using the Mann–Whitney U test for independent samples.

### RESULTS

Reliability results showed a kappa of more than 0.90 for both the osseous maturation and skeletal relation determination.

Descriptive statistics were used to summarize the sample characteristics according to sex and CS skeletal maturation stages (Tables 1 and 2).

The mean age in class I malocclusion subjects with CS3 skeletal maturation stage was 11 years and 9 months. For the same skeletal maturation stage, the mean age of class II malocclusion patients was 11 years and 11 months. No statistical significant difference was found ( $p=0.936$ ). Moreover, no significant statistical difference was found for class I malocclusion (12 years and 7 months) and class II malocclusion (12 years and 5 months) subjects with CS4 ( $p=0.938$ ) (Table 3).

The duration of the adolescent peak growth spurt between CS3 and CS4 for class I malocclusion subjects was 10 months, whereas it was only 6 months for class II malocclusion subjects. This four month difference was statistically significant ( $p<0.001$ ) (Table 4).

**Table 2: Characteristics of the sample by of cervical vertebral stages and skeletal relation.**

Group	Measurement	n	X	SD	Min	Max
Class I – CS3	ANB angle	41	2.70	1.05	0.50	4.00
	FMA angle	41	26.46	1.70	23.00	28.00
Class I – CS4	ANB angle	34	2.65	1.11	0.50	4.00
	FMA angle	34	25.92	1.77	23.00	27.00
Class II – CS3	ANB angle	43	6.12	1.29	5.50	9.00
	FMA angle	43	31.7	1.05	30.00	33.00
Class II – CS4	ANB angle	36	6.24	1.86	5.50	9.50
	FMA angle	36	32.00	1.85	30.00	34.00

**Table 3: Age of onset of cervical vertebral stages by skeletal relation.**

Skeletal relation	Cervical vertebral stage	Age					p
		n	X	SD	Min	Max	
Class I	CS3	41	11y 9m	1y 4m	9y	13y 9m	0.936*
Class II	CS3	43	11y 11m	10m	10y 10m	14y 5m	
Class I	CS4	34	12y 7m	1y 6m	10y 2m	14y 11m	0.938*
Class II	CS4	36	12y 5m	9m	11y 3 m	14y	

\* Mann–Whitney U test for independent samples

**Table 4: Mean interval duration of the peak puberal interval on Class I and II subjects.**

Skeletal relation	Cervical stage			CI inferior limit	CI superior limit	p
	CS3	CS4	CS3-CS4			
Class I	11 y 9 m	12 y 7m	10 m	3m	18m	<0.001*
Class II	11 y 11 m	12 y 5 m	6 m	3m	12m	

\* Mann–Whitney U test for independent samples

## DISCUSSION

The results of this study blend nicely with the results from a previous study by Kuc-Michalska & Baccetti<sup>15</sup>, who determined that the adolescent peak growth spurt is longer in class III than in class I malocclusions. The current result adds more information by determining that the adolescent peak growth spurt is longer in class I than in class II malocclusions. So, in essence, it is now known that progressively, class III malocclusions have a longer adolescent peak growth spurt than class I malocclusions, which indeed have a longer adolescent peak growth spurt than class II malocclusions. The difference in length is 5-6 months between malocclusion types. This information is useful and has significant clinical implications, as a shorter length of the adolescent peak growth spurt in class II malocclusions means a shorter treatment time to maximize potential mandibular growth. It also has to be considered that this means that the chances of missing the adolescent peak growth spurt are increased when craniofacial growth of a patient is not monitored closely. The cervical vertebral maturation diagnostic system uses morphological changes in the cervical vertebrae observed on lateral cephalometric radiographs to determine craniofacial skeletal maturity. It is a widely used approach because lateral cephalograms are routinely taken as orthodontic diagnostic radiographs. So instead of the hand-wrist x-rays that were used in the past, the orthodontist can now theoretically determine the craniofacial skeletal maturation status from a tool that is normally used. CVM method has been proposed as an effective diagnostic tool to assess the adolescent peak growth spurt both in body height and mandibular size<sup>5,15-18</sup>. This method has also been suggested as extremely useful for orthodontic decision making or for the long-term evaluation of treatment outcomes.<sup>6</sup> Nonetheless, the method has a few detractors, who have warned that CVM has only a moderate level of correlation with the individual's skeletal maturation<sup>1-3</sup>, so calibration and training are prerequisites for correct diagnosis in a study, as was done in this research, since the information was collected by a qualified, trained orthodontist. The appearance of a visible concavity at the lower border of the third cervical vertebra is the anatomic characteristic that primarily accounts for the identification of the stage immediately preceding the peak in mandibular growth<sup>4,7,17</sup>. This was also seen on CS3 and CS4 for class I and II subjects in our study. Baccetti *et al.*<sup>7</sup> found that the peak in mandibular growth

occurs between CS3 and CS4. Furthermore, Hassel & Farman<sup>4</sup> report that by looking briefly at the cervical vertebrae on a lateral cephalometric radiograph, the orthodontist can now evaluate the patient's skeletal maturity and have a reasonable idea of how much growth should be factored into anticipated treatment. In the present study, a statistically significant difference of four months was found for the peak growth duration in class I and II subjects. This difference may be a key factor in mandibular growth. Similarly, Kuc-Michalska & Baccetti<sup>15</sup> found a five month difference between class I and class III subjects. The mean age of study subjects was similar to that in previously reported studies<sup>4,18,19</sup>. Zaror & Paniagua<sup>20</sup> reported that CS3 stage is the ideal phase to start functional apparatus therapies for correcting mandibular deficiencies, as peak mandibular growth will occur during the current year to this observation. In addition, the mean time of the onset peak of growth for class I subjects was 11 years and 9 months. A similar time was found for class II subjects (11 years and 11 months). Kuc-Michalska & Baccetti<sup>15</sup> found a mean time of puberal peak of 11 years and 5 months in class I and II subjects.

A systematic review by Santiago *et al.*<sup>1</sup> reported a low level of validity and reliability in cross-sectional studies, suggesting that CVM methods should be used with extreme caution. In growth and development studies, longitudinal studies are an essential method for evaluating craniofacial growth. Gu & McNamara<sup>10</sup> performed a longitudinal study on 20 subjects where the cervical vertebral maturation was evaluated in six consecutive phases and the adolescent peak growth spurt was observed during stages CS3 and CS4. According to Soegiharto *et al.*,<sup>21</sup> there are difficulties in obtaining a large enough sample size because of the associated increase in the number of radiographic exposures, which tends to make this methodology difficult. This is why a cross-sectional design was applied in this study. Subjects were matched for skeletal class, sex and mandibular plane divergence.

The reproducibility of the cervical vertebral method has been studied by several authors<sup>1-3</sup>. Gabriel *et al.*<sup>2</sup> reported moderate inter- and intra-observer agreement. Nestman *et al.*<sup>3</sup> found an inter-observer agreement below 50% and an intra-observer agreement of 62%. Santiago *et al.*<sup>1</sup> obtained moderate to high reproducibility using the same method (Kappa coefficient). It was therefore concluded that it is difficult to reliably classify vertebral body shapes, which by default explains the reported variation of the CVM

method reproducibility. In our study, inter- and intra-observer reproducibility was greater than 0.9, which implies adequate reproducibility. Having said so, accuracy cannot be ensured, as no gold standard was available for this sample. This should be considered when using the results of this study clinically.

In summary, it was concluded that in class I malocclusion subjects, the interval between CS3 and CS4 (duration of the adolescent peak growth spurt) was 10 months, whereas a duration of 6 months was found in class II malocclusion subjects. A difference of 4 months was therefore found between class I and class II malocclusion subjects. This difference should be clinically useful, as a shorter length of the adolescent

peak growth spurt in class II malocclusions could mean a shorter treatment time to efficiently maximize potential mandibular growth. This could also mean that the chances of missing the adolescent peak growth spurt are increased due to the relatively small opportunity window in relation to our usual facial growth monitoring time frames.

## CONCLUSION

The mean time of onset for the adolescent peak growth spurt was similar in class I and II malocclusion subjects. A significant difference of 4 months (10 vs. 6 months respectively) was found in adolescent peak growth spurt duration between class I and II malocclusion subjects.

## ACKNOWLEDGMENT

We would like to thank the CDI Diagnostic Center and its president, Dr. Hugo Aguayo Olivares.

## CORRESPONDENCE

Dr. Rodrigo Salazar Lazo  
Facultad de Odontología, Universidad de Ciencias aplicadas  
Lima, Peru.  
rsalazar68@gmail.com luchoarriola@gmail.com

## REFERENCES

1. Santiago RC, de Miranda Costa LF, Vitral RW, Fraga MR, Bolognese AM, Maia LC. Cervical vertebral maturation as a biologic indicator of skeletal maturity. *Angle Orthod* 2012; 82:1123-1131.
2. Gabriel DB, Southard KA, Qian F, Marshall SD, Francis RG, Southard TE. Cervical vertebrae maturation method: poor reproducibility. *Am J Orthod Dentofacial Orthop* 2009;136:478 e471-477; discussion 478-480.
3. Nestman TS, Marshall SD, Qian F, Holton N, Francis RG, Southard TE. Cervical vertebrae maturation method morphologic criteria: poor reproducibility. *Am J Orthod Dentofacial Orthop* 2011;140:182-188.
4. Hassel B, Farman AG. Skeletal maturation evaluation using cervical vertebrae. *Am J Orthod Dentofacial Orthop* 1995; 107:58-66.
5. Lamparski D. Skeletal age assessment utilizing cervical vertebrae. [Thesis.] Pittsburgh: University of Pittsburgh, 1972.
6. Baccetti T, Franchi L, McNamara JA Jr. An improved version of the cervical vertebral maturation (CVM) method for the assessment of mandibular growth. *Angle Orthod* 2002; 72:316-323.
7. Baccetti T, Franchi L, McNamara J Jr. The cervical vertebral maturation (CVM) method for the assessment of optimal treatment timing in dentofacial orthopedics. *Semin Orthod*. 2005;11:119-129.
8. Chen F, Terada K, Hanada K. A new method of predicting mandibular length increment on the basis of cervical vertebrae. *Angle Orthod*. 2004;74:630-634.
9. Steiner CC. Cephalometrics in clinical practice. *Angle Orthod* 1959; 29:8-29.
10. Gu Y, McNamara JA. Mandibular growth changes and cervical vertebral maturation. a cephalometric implant study. *Angle Orthod* 2007;77:947-953.
11. Northway RO, Jr., Alexander RG, Riolo ML. A cephalometric evaluation of the old Milwaukee brace and the modified Milwaukee brace in relation to the normal growing child. *Am J Orthod* 1974;65:341-363.
12. Steiner CC. Cephalometrics for you and me. *Am J Orthod* 1953;39:729-55.
13. Interlandi S, Scanavini MA. Comparative study of "model discrepancies" and "cephalometric discrepancies". *Rev Fac Odontol Sao Paulo* 1970;8:195-201.
14. Abdullah RT, Kuijpers MA, Berge SJ, Katsaros C. Steiner cephalometric analysis: predicted and actual treatment outcome compared. *Orthod Craniofac Res* 2006;9:77-83.
15. Kuc-Michalska M, Baccetti T. Duration of the pubertal peak in skeletal Class I and Class III subjects. *Angle Orthod* 2010;80:54-57.
16. Reyes BC, Baccetti T, McNamara J Jr. An estimate of craniofacial growth in class III malocclusion. *Angle Orthod* 2005;76:577-584.
17. San Roman P, Palma JC, Oteo MD, Nevado E. Skeletal maturation determined by cervical vertebrae development. *Eur J Orthod* 2002;24:303-311.
18. Franchi L, Baccetti T, McNamara JA, Jr. Mandibular growth as related to cervical vertebral maturation and body height. *Am J Orthod Dentofacial Orthop* 2000;118:335-340.
19. Uysal T, Ramoglu SI, Basciftci FA, Sari Z. Chronologic age and skeletal maturation of the cervical vertebrae and hand-wrist: is there a relationship? *Am J Orthod Dentofacial Orthop* 2006;130:622-628.
20. Zaror R, Paniagua H. Método de evaluación cervicovertebral y su relación con la oportunidad de tratamiento con claseII dentoescelética. *Int J Odontostomat* 2008;2: 27-31.
21. Soegiharto BM, Moles DR, Cunningham SJ. Discriminatory ability of the skeletal maturation index and the cervical vertebrae maturation index in detecting peak pubertal growth in Indonesian and white subjects with receiver operating characteristics analysis. *Am J Orthod Dentofacial Orthop* 2008;134:227-237.