

INFLUENCE OF CANTILEVER LENGTH AND TYPE OF ARCH ANTAGONIST ON BONE LOSS IN TOTAL IMPLANT-SUPPORTED PROSTHESES

Rafaella M.O. Cid^{1,2}, Kyle Stanley^{1,2}, Ernesto B. Cordero², Cesar A.M. Benfatti², Marco A. Bianchini²

¹ Herman Ostrow School of Dentistry of University of Southern California, Los Angeles, California, United States.

² Center for Health Sciences, Department of Dentistry, Federal University of Santa Catarina Florianopolis, Santa Catarina, Brazil.

ABSTRACT

This study selected forty-two implants with full arch implant-supported fixed prostheses (with and without a cantilever) with at least five years' loading. Radiographic measurements were performed using Digimizer software (MedCalc Software, Belgium). Bone loss was measured on the distal side of the implant, from the surface of the platform to the edge of the bone crest, and the extent of the cantilever was measured from the distal surface of the last abutment to the end of the metal structure. Three groups were formed according the length of the cantilever: G1: cantilever ≤ 15 mm; G2: cantilever > 15 mm; G3: no cantilever. Types of antagonists were grouped as: RP = removable complete denture; FP = fixed implant-sup-

ported prosthesis; ND = natural dentition. Data were analyzed according to the length of the cantilever and type of antagonist using Person's test to analyze normality and Student's *t*-test with $P \leq 0.05$. No statistically significant difference was found between G1 and G2; however, increased bone loss was observed in both cantilever groups (G1 and G2) compared to G3 ($P > 0.05$). The antagonist showed no significant difference in bone loss ($P \leq 0.05$). Cantilevers showed increases in marginal bone loss. The type of antagonist did not influence bone loss.

Key words: Rehabilitation; Alveolar Bone Loss; Implant-supported dental prosthesis.

INFLUÊNCIA DA EXTENSÃO DO CANTILEVER E DO ARCO ANTAGONISTA SOBRE A PERDA ÓSSEA EM PRÓTESES TOTAIS IMPLANTOSUPORTADAS

RESUMO

O estudo selecionou quarenta e dois implantes que possuíam próteses totais implantosuportadas (com e sem cantilever) instaladas a pelo menos cinco anos. As radiografias foram mensuradas através do software Digimizer (MedCalc Software, Bélgica). A mensuração da perda óssea foi realizada na distal dos implantes, a partir da superfície da plataforma do implante até a crista óssea marginal; e a extensão do cantilever foi mensurada a partir da superfície do implante distal até a extremidade da estrutura da prótese. Três grupos foram formados de acordo com comprimento do cantilever: G1 = ≤ 15 mm, G2 = > 15 mm; G3 = sem cantilever. O tipo de antagonista foi agrupado em: RP = prótese removível; FP = prótese fixa

implanto-suportada; ND = dentição natural. A análise dos dados foi realizada de acordo com a extensão do cantilever e o tipo de arco antagonista. Utilizou-se o teste estatístico de Person's para verificação da normalidade e Test *t* de Student com valor de $P (P \leq 0.05)$. Ao comparar G1 e G2, não houve diferença estatisticamente significativa, no entanto, uma perda óssea aumentada foi observada em ambos os grupos com cantilever (G1 e G2) quando comparados ao G3. Extensões de cantilever irão causar um aumento na perda óssea marginal, porém o tipo de antagonista não irá influenciar esta perda óssea.

Palavras-chave: Reabilitação; Perda óssea Alveolar; prótese total implantosuportada.

INTRODUCTION

Although the choice of complex dental treatment may be limited by its expense and the morbidity involved in certain clinical situations such as bone deficiencies and/or the presence of anatomical structures¹, the number of treatments with fixed implant-supported prostheses has increased considerably.

One alternative is a complete fixed implant supported prosthesis (CFISP), which usually requires an extension of prosthetic structures bilaterally from the most distal implant, called a cantilever²⁻⁴. The obvious clinical advantages of CFISP include shorter treatment time, lower cost, and the fact that it does not require complex reconstructive surgeries^{4,5}.

The definition of a cantilever, according to the Glossary of Prosthodontics terms⁶, is a fixed bridge with a free end that is supported and retained only on one end by one or more abutments. Initially, it was suggested that the length of the cantilever should be limited to the size of two teeth after the last implant in the mandible, and only one tooth in the maxilla, in order to minimize the potential torque transmitted to the implants and the surrounding bone⁷. Some authors²⁻⁷ suggest that excessively long cantilevers increase the risk of complications. Shackleton et al.³ evaluated two cantilever lengths (≤ 15 mm and > 15 mm) for fixed prostheses on implants, and concluded that short cantilevers had better clinical performance than long cantilevers.

Sertgöz et al.² evaluated the distribution of stress at the implant/bone interface and found that increased length of the cantilever resulted in higher values of stress at the interface. The incorporation of the cantilever in CFISPs has resulted in an increased magnitude of forces on the crestal bone around the implants, and this overload is proportional to the length of the cantilever⁴⁻⁸.

However, in a prospective study⁹, the performance of mandibular implant-supported complete dentures was evaluated clinically. The success rates for implants and prostheses were 98.9 and 95.6% respectively. The most common complication is the loosening of the prosthetic retaining screws and bone loss around the most distal implant¹⁰, specifically on the distal surface closest to the extension where the greatest stress occurs¹⁰⁻¹¹. Another factor that contributes to an increased rate of complications is the type of antagonist³.

According to Naert et al.¹², several factors contribute to prosthesis-related increased bone loss in the peri-implant region, including the height of the abutment, the type of material used on the occlusal

surface and the type of antagonist. An experimental animal model showed that excessive static load on implants did not result in marginal bone loss or loss of osseointegration, but that the bone adjacent to the implants loaded showed a higher density compared with unloaded implants¹³.

Naert et al.¹⁴ reported data of 91 jaws that were treated with complete fixed prostheses supported by Brånemark implants (n = 589). The authors concluded that for three years, the length of the cantilever had a significant impact on the amount of marginal bone loss around implants.

The aim of this study is to evaluate marginal bone loss over the most distal implants in full arch fixed implant supported dentures with cantilevers longer than 15 mm, shorter than or equal to 15 mm and without cantilevers, and the influence of the type of antagonist on peri-implant bone loss. The null-hypothesis is that the opposing arch and cantilever length do not influence bone loss around the distal implants of full arch implant supported fixed dentures.

METHODS

The patients were selected from the Center for Teaching and Research in Dental Implants (CEPID), Department of Dentistry, Federal University of Santa Catarina - UFSC (Florianopolis, Santa Catarina, Brazil), who were treated with dental implants between 2002 and 2012 (a 10-year period). Forty-two implants were analyzed from a database, including 22 female patients (12 maxilla and 10 mandibles) and 20 male patients (10 maxilla and 10 mandibles), aged 43-87 years (Table 1), with full arch fixed implant-supported prostheses (with and without cantilever) installed at least 5 years prior to the study evaluation.

Inclusion criteria

All edentulous patients included had worn their prosthesis for at least five years and were referred for evaluation or re-evaluation of their implant-supported fixed prostheses. They signed an informed consent as provided by the Ethics Committee of Research in Humans of the Federal University of Santa Catarina – UFSC (protocol number: 128/2006). All patients demonstrated adequate oral hygiene and absence of any local inflammation. In addition, neither residual roots nor mucosal diseases were present and there was adequate bone height for the placement of dental implants.

Table 1: The Patients divided according to gender, age and implant location.

Gender	Age (mean)	Implant Location	Total
Female	50	Maxilla	12
Female	47	Mandible	10
Male	55	Maxilla	10
Male	66	Mandible	10

Exclusion criteria

Excluded from this study were patients that used tobacco, alcohol or other drugs, those who had severe bruxism or clenching habits, poor general health, were pregnant, had a history of radiation to the head and neck, previous grafting at the surgical sites, lack of motivation or physical handicaps that would prevent proper oral hygiene.

Implant placement and prosthodontic treatment

Patients received prophylactic antibiotic regime before surgery (Amoxicillin 500mg) and oral rinse with 0.12% chlorhexidine gluconate for 1 minute for local disinfection. The peri-oral skin was washed with a skin disinfectant. Rough surface one-piece implants were placed under local anesthesia and aseptic conditions with a surgical handpiece with a maximum drilling speed of 1200 rpm and plentiful cooling with sterile saline. External hex implants with regular platform of two commercial brands (Conexão Sistemas de Prótese, São Paulo, SP, Brazil and Neodent, Curitiba, PR, Brazil) were placed. Healing caps were placed and flaps were sutured. After implant placement, the old dentures were relieved completely from direct implant contact and adjusted with soft reline material (GC America Inc. - Leuven, Belgium). All patients were instructed on post-operative home care. Three to six months after implant placement, the patients returned to receive the final implant-supported denture. All prostheses were screw-retained.

Radiographic Examinations

A General Electric model 1000x-ray machine (General Electric Co., Milwaukee, WI, USA) operating at 65kVp and 10 mA, with an aluminum filter 1.5 mm thick was used to take standardized periapical radiographs (Kodak Insight film, Carestream, INC., New York, EUA) of each distal implant using the paralleling technique with an occlusal bite index prepared with a repositioning jig. The bite index was saved to be used at all visits.

The radiographs were digitized using a slide scanner (SprintScan 35, CS-2700, Polaroid Scanner, Cambridge, MA, USA), 600 d.p.i. resolution, and 256 grey levels. The images were coded so that they could be blinded and stored in JPEG File Format without compression.

The radiographs were then measured using Digimizer software (MedCalc Software, Belgium). Bone loss

was measured on the most distal portion of the implant, from the surface of the platform to the edge of the crystal bone, and the length of the cantilever was measured from the distal surface of the last abutment to the end of the metal structure (Fig. 1)³. The patients were then divided into three groups according to the length of the cantilever and type of antagonist. Data were analyzed using Stata 9 (Stata Corp., College Station, TX, EUA) with Person's to analyze normality and Student's t-test. The significance level was set at $P \leq 0.05$.

RESULTS

A total 42 distal implants were measured out of 110 implants placed to support complete fixed dentures. These implants were then divided into 3 groups according to the cantilever length: 22 with cantilever ≤ 15 mm, 10 with cantilever > 15 mm and 10 without a cantilever (total 42) (Table 2). The length of the distal cantilever extension (i.e. > 15 mm and ≤ 15 mm) was based on previous research that demonstrated the influence of cantilever length on the survival rate of complete fixed prostheses³. According to the type of antagonist, there were 8 patients with traditional complete dentures, 17 with fixed prostheses (implant-supported prosthesis) and 17 with natural teeth (Table 3). No statistically significant difference was found between groups 1 and 2, but groups 1 and 2 differed significantly from group 3 ($p \leq 0.05$) (Figs 2 and 3). There was no statistical significance between types of antagonist (Fig. 4).




Fig. 1: X-ray showing the measurements of bone loss related to cantilever length.

Table 2: The groups divided according to length of their cantilevers.

Group	Total
Cantilever \leq 15 mm	22
Cantilever > 15 mm	10
Absence of cantilever	10

Table 3: The groups divided according to type of antagonist.

Antagonist	Total
Removable complete denture	8
Fixed Prosthesis	17
Natural Teeth	17

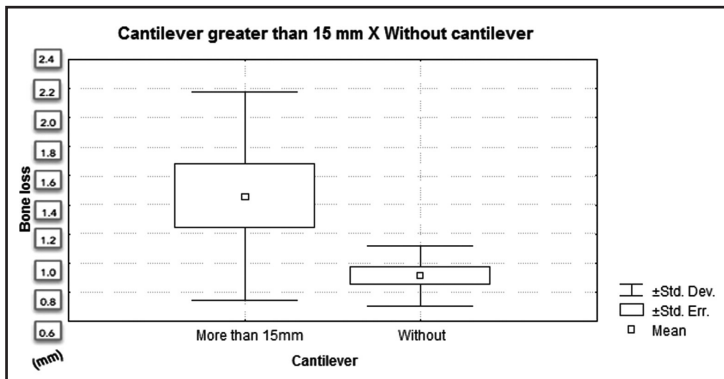


Fig. 2: Bone loss with cantilever longer than 15mm or without cantilever.

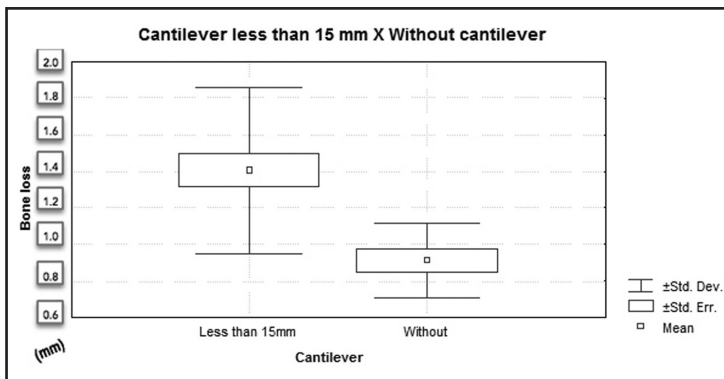


Fig. 3: Bone loss with cantilever shorter than 15mm or without cantilever.

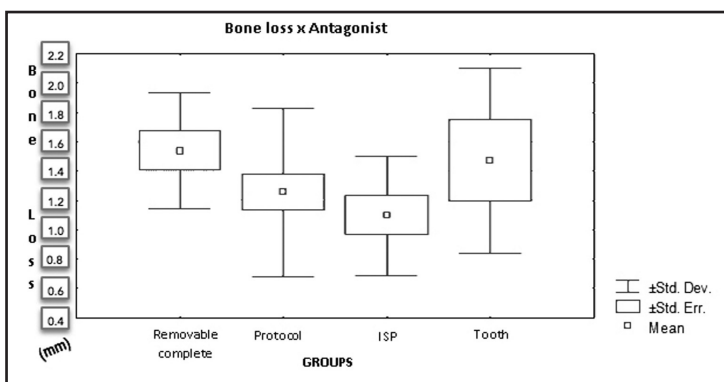


Fig. 4: Comparison of bone loss related to the type of antagonist.

DISCUSSION

The implant supported fixed complete denture with a cantilever extension is a simple restoration often used for the rehabilitation of edentulous patients^{4,11}. In this study we used a comparative model following Shackleton et al.³, which compares cantilever lengths shorter than or equal to 15 mm and longer than 15 mm^{3,15}. Other authors advocate the use of 6 implants with cantilever lengths \leq 10 mm in the maxilla. However, for the mandible, five implants are recommended according to the Branemark protocols¹².

To allow an even distribution of functional forces to the bone without overloading the implant/bone interface, the length of the cantilever should not exceed 15 mm in the mandible³ and 10 mm in the maxilla¹¹. Cantilever length must be less than 10 mm in the maxilla due to the poor bone quality in this region. The inclusion of cantilevers in fixed prosthodontics is considered an important risk factor. In the present study, when comparing bone loss in relation to the length of the cantilever (G1: cantilever \leq 15mm and G2: cantilever > 15mm), there was no statistical difference between groups.

The literature reports the benefit of more posterior support, which minimizes mechanical stress on the prosthesis in an ‘all-on-four’ situation¹⁶⁻¹⁸. In this study there was a statistically significant difference between the groups with and without cantilevers, with greater bone loss around implants with cantilevers.

Bone loss was reported in two others studies in which radiographic bone level

changes around implant supporting prostheses with cantilever extensions were compared to implant-supported FPDs without cantilever extensions (IFDPs). The radiographic bone level showed slightly greater bone loss around implants close to the cantilever extensions. However, no statistically significant difference was found, with a summary estimate of difference in bone loss per year of 0.033 (95% CI: 0.02–0.087; $p > 0.05$)^{19,20}.

Romeo et al.²¹ reported that after an average of three years, the amount of bone loss in the most distal implant, adjacent to the cantilever, was totally correlated with the cantilever extension. In a clinical follow-up study conducted by Ekelund et al.⁹ with over 15 years of observations, patients rehabilitated with implant supported fixed dentures had a success rate exceeding 90% in relation to bone loss. This study revealed a similar success rate of 93%, suggesting that removable prosthesis, fixed prosthesis and natural teeth as cantilever antagonists did not influence bone loss.

Romeo et al.²¹ also reported no significant difference in peri-implant bone resorption among different types of antagonists. On the contrary, the frequency of prosthetic complication was significantly higher for the prostheses with cantilever extensions opposite implant-supported restora-

tions (58.3% VS. 38.3%). More evidence is needed to confirm these results.

Pjetursson et al. (2004)²² in a systematic review, found a survival rate of 95% (95% CI 92.2 to 96.8) after 5 years on implant-supported prostheses with cantilevers. Other authors²¹⁻²⁵ found that peri-implant bone loss is more pronounced in the maxilla than the mandible.

The most frequent technical complications in implant supported prostheses with cantilevers included veneer fractures, followed by screw loosening and loss of retention²². No detrimental effects on bone levels were observed around implants close to the cantilever extensions. However, there is as yet little evidence of the effects of various prosthetic designs (e.g. distal or mesial cantilever extension), number of implants and occlusal concepts on the incidence of complications in a complete implant supported denture.

The null hypothesis was partially confirmed. According to the methodology used and the limitations of this study, it was concluded that implant supported fixed dentures with a cantilever extension show greater bone loss than those without cantilevers, but the lengths of the cantilevers (shorter than 15 mm and longer than 15 mm) revealed no significant difference. The opposing antagonist arch had no direct influence on bone loss.

CORRESPONDENCE

Dr. Rafaella M. O. Cid
 Universidad Federal de Santa Catarina
 Centro de Ciências da Saúde
 Departamento de Odontologia
 Campus Universitário, SN
 CEP 88040-970 – Trindade – Florianópolis - SC - Brasil
 rafaellacid22@hotmail.com

REFERENCES

1. Chiapasco M, Zaniboni M, Boisco M. Augmentation procedures for the rehabilitation of deficient edentulous ridges with oral implants. *Clin Oral Implants Res* 2006;17:136-159.
2. Sertgöz S, Güvener S. Finite element analysis of the effect of cantilever and implant length on stress distribution in an implant-supported fixed prosthesis. *J Prosthet Dent* 1996; 76:165-169.
3. Shackleton JL, Carr L, Slabbert JC, Becker PJ. Survival of fixed implant-supported prostheses related to cantilever lengths. *J Prosthet Dent* 1994;71:23-26.
4. Rodriguez AM, Aquilino SA, Lund PS. Cantilever and implant biomechanics: a review of the literature Part 2. *J Prosthodont* 1994;3:114-118.
5. Aglietta M, Siciliano VI, Zwahlen M, Brägger U, Pjetursson BE, Lang NP, Salvi GE. A systematic review of the survival and complication rates of implant-supported fixed dental prostheses with cantilever extensions after an observation period of at least 5 years. *Clin Oral Implants Res* 2009;20: 441-451.
6. The Glossary of Prosthodontic Terms. *J Prosthet Dent* 2005; 94:10-92.
7. Adell R, Lekholm U, Rockler B, Brånemark PI. A 15-year study of osseointegrated implants in the treatment of the edentulous jaw. *Int J Oral Surg* 1981;10:387-416.
8. Rangert B, Krogh PH, Langer B, Van Roekel N. Bending overload and implant fracture: a retrospective clinical analysis. *Int J Oral Maxillofac Implants* 1995;10:326-334.

9. Ekelund JA, Lindquist LW, Carlsson GE, Jemt T. Implant Treatment in the Edentulous Mandible: A Prospective Study on Branemark System Implants over More than 20 Years. *Int J Prosthodont* 2003;16:602-608.
10. Calandriello R, Tomatis M. Simplified treatment of the atrophic posterior maxilla via immediate/early function and tilted implants: A prospective 1-year clinical study. *Clini-Implant Dent Relat Res* 2005;7:S1-12.
11. Greco GD, Jansen WC, Landre Junior J, Seraidarian PI. Stress analysis on the free-end distal extension of an implant-supported mandibular complete denture. *Braz Oral Res* 2009; 23:182-189.
12. Naert I, Duyck J, Hosny M, Jacobs R, Quirynen M, van Steenberghe D. Evaluation of factors influencing the marginal bone stability around implants in the treatment of partial edentulism. *Clin Implant Dent Relat Res* 2001;3:30-38.
13. Gotfredsen K, Berglundh T, Lindhe J. Bone reactions adjacent to titanium implants subjected to static load of different duration. A study in the dog (III). *Clin Oral Implants Res* 2001; 12:552-558.
14. Naert I, Quirynen M, van Steenberghe D, Darius P. A study of 589 consecutive implants supporting complete fixed prostheses. Part II: Prosthetic aspects. *J Prosthet Dent* 1992; 68:949-956.
15. Renouard F, Rangert B. Risk factors in implant dentistry. 1st Ed. Chicago: Quintessence Publishing Co. 1999; chap 3; 39-66.
16. Krekmanov L, Kahn M, Rangert B, Lindström H. Tilting of posterior mandibular and maxillary implants of improved prosthesis support. *Int J Oral Maxillofac Implants* 2000; 15:405-414.
17. Capelli M, Zuffetti F, Del Fabbro M, Testori T. Immediate rehabilitation of the completely edentulous jaw with fixed prostheses supported by either upright or tilted implants: a multicenter clinical study. *Int J Oral Maxillofac Implants* 2007;22:639-644.
18. Testori T, Del Fabbro M, Capelli M, Zuffetti F, Francetti L, Weinstein RL. Immediate occlusal loading and tilted implants for the rehabilitation of the atrophic edentulous maxilla: 1-year interim results of a multicenter prospective study. *Clin Oral Implants Res* 2008;19:227-232.
19. Wennström J, Zurd J, Karlsson S, Ekkestubbe A, Gröndahl K, Lindhe J. Bone level change at implant-supported fixed partial dentures with and without cantilever extension after 5 years in function. *J Clin Periodontol* 2004;31:1077-1083.
20. Hälgl GA, Schmid J, Hämmerle CH. Bone level changes at implants supporting crowns on fixed partial dentures with or without cantilevers. *Clin Oral Implants Res* 2008; 19:983-990.
21. Romeo E, Lops D, Margutti E, Ghisolfi M, Chiapasco M, Vogel G. Implant-supported fixed cantilever prostheses in partially edentulous arches. A seven-year prospective study. *Clin Oral Implants Res* 2003;14:303-311.
22. Pjetursson BE, Tan K, Lang NP, Brägger U, Egger M, Zwahlen M. A systematic review of the survival and complication rates of fixed partial dentures (FPDs) after a observation period of at least 5 years. *Clin Oral Implants Res* 2004;15:625-642.
23. Närhi TO, Geertman ME, Hevinga M, Abdo H, Kalk W. Change in edentulous maxilla in persons wearing implant-retained mandibular overdentures. *J Prosthet Dent* 2000; 84:43-49.
24. Abd El-Dayem MA, Assad AS, Abdel-Ghany MM. The effect of different mandibular dentures on antagonistic maxillary ridge. *Implant Dent* 2007;16:421-429.
25. Sağlam AA. The vertical heights of maxillary and mandibular bones in panoramic radiographs of dentate and edentulous subjects. *Quintessence Int* 2002;33:433-438.