

EFFICACY OF CORE NEEDLE BIOPSY TECHNIQUE FOR JAWBONE DISEASES

Federico Stolbizer^{1,2}, Romulo L. Cabrini³, Alicia Keszler³

¹ Emergency Department.

² Department of Oral-maxillofacial Surgery.

³ Oral Pathology Department, School of Dentistry University of Buenos Aires. Argentina.

ABSTRACT

Core needle biopsy (CNB) has been proven useful for diagnosing bone lesions, although it is not often used for jawbone lesions. The aim of this study was to evaluate the efficacy of the CNB method in a series of cases of intramaxillary lesions.

CNB was performed on 85 patients with intraosseous lesions which were grouped according to radiographic appearance as: radiopaque lesions (RO, n=13), radiolucent lesions (RL, n=39) and mixed lesions with both radiolucent and radiopaque areas (RL-RO, n=33). The technique enabled us to obtain several tissue cylinders from each lesion (average 2.5 cylinders), which were processed following routine histopathological technique

and H&E stain, plus special techniques when necessary. The histopathological analysis together with clinical data enabled accurate diagnosis (AD) in 81% of the cases and descriptive diagnosis (DD) in 14%. The material obtained in 5% of the cases was not appropriate for study (ND). The difference between successful (AD) and unsuccessful (DD+ND) CNB cases is statistically significant.

The highest percentage of successful CBNs was for RO and RL-RO lesions (85% and 100% respectively). RL lesions were more difficult because most of them were cystic lesions with fluid content.

Key words: Core needle biopsy; jaw diseases.

EFICACIA DE LA TÉCNICA DE PUNCIÓN ÓSEA PARA BIOPSIA DE LESIONES DE MAXILARES

RESUMEN

La biopsia-punción ósea (Core needle biopsy, CNB) es un procedimiento de probada utilidad en el diagnóstico de lesiones óseas. Sin embargo, no es una técnica de uso frecuente en las lesiones de los maxilares. La finalidad de este trabajo fue evaluar la eficacia del método de CNB en una serie de casos de lesiones intramaxilares.

Se realizaron CNB en 85 pacientes con lesiones intraóseas, las cuales fueron agrupadas según su aspecto radiográfico en lesiones radiopacas (RO, n=13), lesiones radiolúcidas (RL, n=39) y lesiones mixtas con sectores radiolúcidos y radiopacos (RL-RO, n=33). La técnica permitió obtener varios cilindros de tejido de cada lesión (promedio: 2.5 cilindros) los cuales fueron procesados según técnica histopatológica de rutina con

tinción de H&E y técnicas especiales en los casos en que fueron necesarias. El análisis de los cuadros histopatológicos conjuntamente con los datos clínicos, permitió realizar un diagnóstico de certeza (AD) en el 81% de los casos y un diagnóstico descriptivo (DD) en el 14%. En el 5% de los casos el material obtenido no fue adecuado para su estudio (ND) La diferencia entre los casos de CNB exitosa y no exitosa (DD+ND) es estadísticamente significativa.

El mayor porcentaje de CBN exitosas correspondió a las lesiones RO y RL-RO (85% y 100% respectivamente) Las lesiones RL presentaron mayor dificultad debido a que, en su mayoría, eran lesiones quísticas con contenido líquido.

Palabras clave: biopsia punción ósea; lesiones de los maxilares.

INTRODUCTION

Biopsy sampling is a surgical procedure for obtaining material from a lesion on which to perform histopathological studies for use together with all the clinical data to reach a diagnosis and provide appropriate treatment. The choice of technique and instruments for taking the biopsy depends on the nature and location of the lesion. For intraosseous lesions, a tissue sample can be obtained by performing either surgical biopsy (open biopsy) or puncture biopsy (closed biopsy).

Since 1901, when the first instrument for performing puncture biopsy was registered¹ great efforts have been made to develop techniques and instruments to avoid the complications that can arise with an open biopsy, particularly when the lesions are located deep inside the tissue or are in contact with vital structures¹⁻¹¹. Progress in these devices has generated great interest among physicians. A number of case series published have shown the efficacy and advantages of using core needle biopsy (CNB), reporting success rates

ranging from 20 to 95%^{1,6,12-19}. The published data demonstrate how the technique has developed and improved over the years.

In contrast to the widespread use of CNB in the field of medicine, and in spite of the frequency and variety of lesions that affect the jaws, the procedure has not had significant application in the field of dentistry. The aim of this study was to assess the efficacy of the CNB method in a series of intramaxillary lesion cases.

MATERIALS AND METHODS

Core needle biopsies were performed on eighty-five patients, 45 female and 40 male, age range 6 to 80 years, with intramaxillary lesions and indication for biopsy. All patients provided informed consent. The project was approved by the Ethics Committee of the School of Dentistry, University of Buenos Aires. The radiographic appearance of biopsied lesions was radiolucent (RL) in 39 cases, mixed radiolucent-radiopaque (RL-RO) in 33 cases, and radiopaque (RO) in 13 cases.

The CNB technique was performed on outpatients under local anesthesia with 4% Articaine Chlorhydrate with L-Adrenaline 1:1000,000 (Bernabó Laboratory, Buenos Aires, Argentina), using 11 gauge/10cm-long needles, originally designed for taking bone marrow samples from the iliac crest, (Gallini medical devices, BM 11G-10cm, Italy). A transmucosal puncture was performed without prior incision. Several samples were taken using the same puncture site and positioning the needle in different directions. The number of samples taken depended in each case on the size of the lesion and the degree of homogeneity in the X-ray image. The operation does not require subsequent suture. The tissue cylinders obtained were fixed in 10% formalin and demineralized in 7% nitric acid for 12-24 h, depending on their degree of mineralization. Following routine embedding in paraffin, sections were obtained and stained with H-E. When special techniques were needed as a diagnostic aid, histochemical and immunohistochemical stains were also performed on adjacent sections. The following techniques were used: Periodic acid Schiff, Gomori's Trichrome stain, and immunohistochemical reactions for the expression of the antigens CK7/20, CD3, CD20, CD1a, S100, Vimentin and kappa and lambda light chains.

After correlating histopathological findings with the individual patients' histories, clinical and image data, final diagnoses were grouped in three categories as follows: 1- Accurate diagnosis (AD), when it was possible to arrive at the diagnosis of a defined pathological entity, 2- Descriptive diagnosis (DD), when the histopathological diagnosis was descriptive but not conclusive, and together with clinical and radiographic data enabled a defined pathology to be suggested, though not identified; 3- No diagnosis (ND), when the quantity or quality of the material obtained from the biopsy was not sufficient to establish a diagnosis.

Final AD diagnoses of biopsy samples obtained by CNB were then confirmed with the study and diagnosis of the surgical specimen, when the treatment of the biopsied lesion was surgery. In cases not requiring surgery, (e.g. fibrous dysplasia) the diagnosis was confirmed through clinical and radiographic follow-up of the patient for at least two years. For the purpose of this study, we did not change the final DD and ND of the CNBs, even if subsequent studies enabled improvement in the diagnosis.

To evaluate the efficacy of the CNB method, the percentage of AD (successful CNBs) was compared to the percentage of DD+ND (unsuccessful CNBs) using the One-Sample Proportion Test.

We also evaluated the percentage of AD, DD and ND with relation to the radiographic appearance of the lesions to determine whether lesion type conditions the success of the CNB. Pearson's Chi-squared test was used for this purpose.

RESULTS

The technique enabled material to be obtained in all cases (100%), with an average of 2.5 tissue cylinders per patient.

CNB diagnosis of a defined entity or accurate diagnosis (AD), subsequently confirmed by the study of the surgically removed tissue or patient follow-up, was achieved in 81% of the cases. Descriptive diagnoses (DD) were made for 14% of the cases and no adequate material for diagnosis (ND) was obtained in 5%. The percentage of successful CNBs (AD) differed statistically from DD + ND (One-Sample Proportion Test, $p=0.005$). Fig. 1 shows an example of the material studied in one case in which accurate diagnosis of ossifying fibroma was made. Table 1 shows final diagnoses of all the study cases.

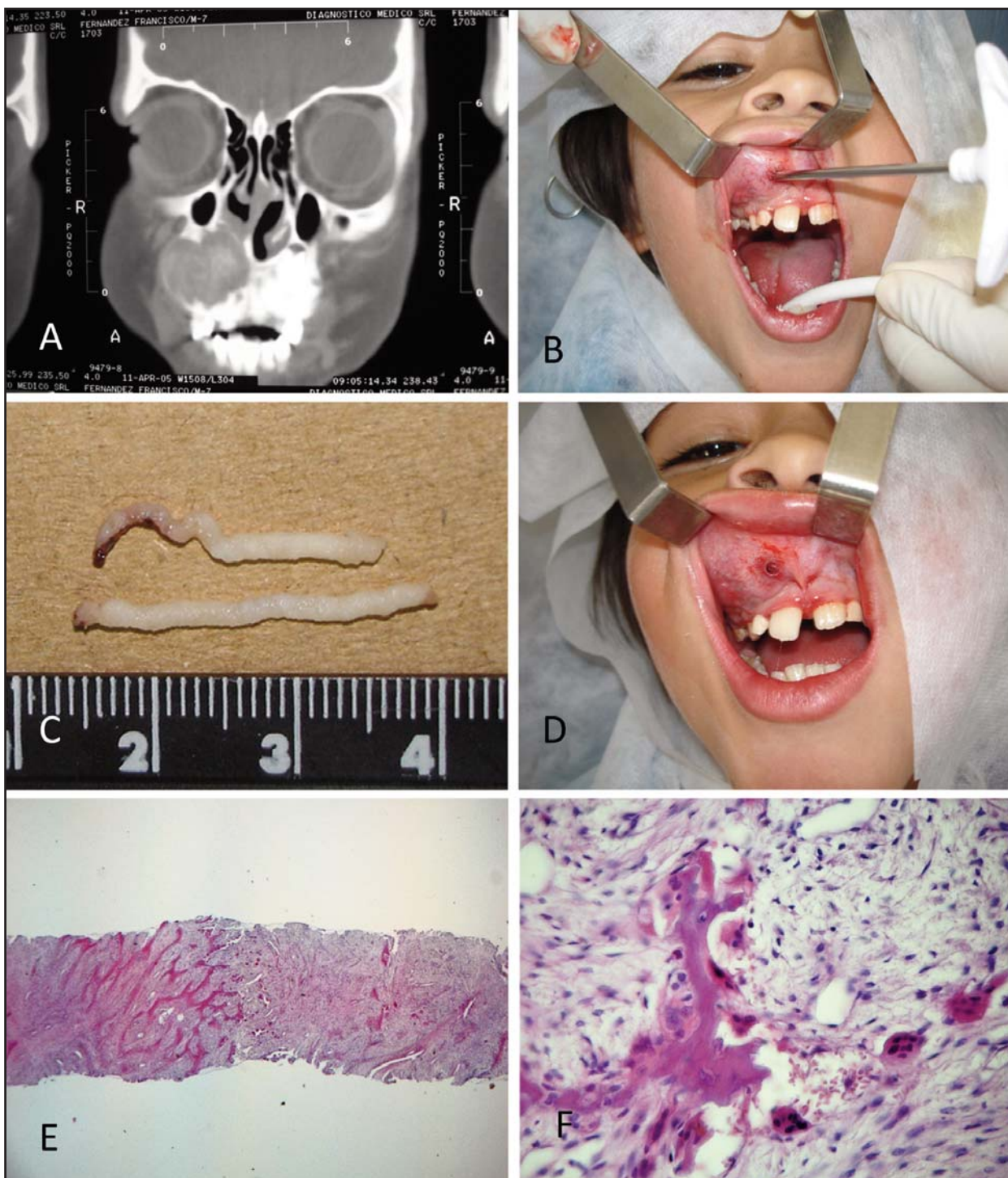


Fig. 1: Lesion in the upper jawbone in which core needle biopsy led to the diagnosis of ossifying fibroma. A) CT image, B) Puncture technique C) Tissue cylinders obtained from the lesion, C) Lesion in the mucosa after puncture, - D-F) Microscopic features. HE. Original magnification X 5 and X 40.

Table 2 shows the distribution of percentages of CNB final diagnoses with relation to the different radiographic appearances. The CNB was effective for all radiologic types of the biopsied lesions.

However, radiolucent lesions were more difficult. The percentage of successful cases is significantly higher in RO and RL-RO lesions (85% and 100% respectively) than in the group of RO lesions

Table 1: Lesions under study and diagnoses of core needle biopsies.

Radiopaque lesions		Radiolucent-Radiopaque lesions		Radiolucent lesions	
	n CNB		n CNB		n CNB
Osteomyelitis	5AD 2DD	Fibrous dysplasia	15AD	Adenocarcinoma Metastasis	3AD 1DD
Chronic Periostitis	2AD	Ossifying fibroma Fibroma osificante	6AD	Lymphoma	4AD
Condensing Osteitis	2AD	Paget's disease	3AD	Squamous Cell Carcinoma	3AD
Odontoma	1AD	Adenocarcinoma Metastasis	2AD	Central Giant cell Granuloma	3 AD
Paget's disease	1AD	Cystic fibrous osteitis (primary HPT)	2AD	Keratocystic Odontog. Tumor	1AD 2DD
		Cherubism	1AD	Langerhans Cell Histiocytosis	2AD
		Gnathodiaphyseal dysplasia	1AD	Hemangioma	1AD 2DD
		Renal osteodystrophy (secondry HPT)	1AD	Radicular Cys	2ND
		Calcifying Epithelial Odontog. Tumor	1AD	Radicular Granuloma	1ND 1DD
		Bone undergoing repair	1AD	Dentigerous Cyst	2DD
				Ameloblastoma	1AD 2DD
				Adenocarcinoma	1AD
				Neuroectodermal Tumor	1AD
				Plasmacytoma	1AD
				Fibromatosis	1DD
				Desmoplastic Fibrosarcoma	1AD
				Malignant Schwannoma	1AD
				Ossifying Fibroma	1AD
				Inverted Papilloma	1AD
				Nasal palatal Cyst	1ND
				Hemorrhagic Cyst	1ND

n: number of cases; CNB diagnoses from core needle biopsy
AD: accurate diagnosis; DD: descriptive diagnosis; ND: no diagnosis

Table 2: Distribution of percentages of CNB final diagnoses for different radiographic appearances.

	AD	DD	ND	n
RO	85%	15%	-	13
RL-RO	100%	-	-	33
RL	64%*	26%	10%	39

RO: radiopaque lesions; RL-RO mixed radiolucent-radiopaque lesions; RL: radiolucent lesions, AD: accurate diagnoses; DD: descriptive diagnoses; ND: no diagnoses, n: number of cases. * different from RO and RL-RO groups. Pearson's Chi-squared test, p=0.002.

(Pearson's Chi-squared test, p=0.002). In RO lesions group diagnosis was conclusive in cases of periostitis, condensing focal osteitis, odontoma, Paget's disease, and in 5 out of the 7 cases of

osteomyelitis. The group of RL-RO lesions included a wide range of pathologies of very different nature. The group of RL lesions, in which 64% of CNBs were successful, included several cystic lesions (Table 2).

DISCUSSION

Core needle biopsy has several advantages over open biopsies. It allows tissue to be obtained from the depth of the lesion, whereas surgical open biopsy is often limited to the periphery of the lesion. This is relevant for large lesions. For smaller lesions, it may be possible to obtain a tissue cylinder for the entire diameter of the lesion. By placing the needle at different angles through a single puncture site, several representative cylinders can be obtained from different zones of the lesion.

This is particularly important when the lesion is large and/or has a heterogeneous radiographic appearance. CNB does not require incisions or sutures, thus shortening the surgical times and being less traumatic, less invasive, and better tolerated by the patient. Moreover, it usually causes less hemorrhage and less contamination of the surgical site and often reduces the cost of surgery.

However, the use of puncture biopsies in the field of maxillofacial surgery is not yet widespread. This may be due partly to the fact that there is easy access to the oral cavity for conventional surgical biopsies. However, once minimal necessary training has been acquired, a specialist surgeon has all the advantages described above.

Some authors have evaluated the use of fine needle aspiration biopsy in intramaxillary lesions, and have found it to have significant diagnostic value²⁰⁻²² in spite of the fact that by using this technique,

material is only obtained for the study of isolated cells. The few papers that refer to the application of CNB in jaw pathologies describe the methodology and report single clinical cases²³⁻²⁶, but we have not found any reports of series of cases evaluating the usefulness of the method. The CNB technique proved effective in radiopaque lesions and radiologically inhomogeneous lesions. The lower efficacy of CNB in radiolucent lesions was due to the fact that this group included six cystic lesions containing fluid, and three keratocystic odontogenic tumors for which a conclusive diagnosis was only achieved in one case, in which a sample of the cystic membrane was obtained.

Assessing the efficacy of CNB according to the radiographic appearance of a lesion is clinically relevant, and would serve in clinical practice as a basis to determine the fastest, simplest, and most suitable biopsy technique in each specific case.

CORRESPONDENCE

Dr. Federico STOLBIZER.

Servicio de Urgencias Facultad Odontología.

Universidad de Buenos Aires

M.T. de Alvear 2146. C1122AAH C.A.B.A. Argentina

e-mail: fstolbizer@hotmail.com

REFERENCES

- Ackermann W. Application of the trephine for bone biopsy. Result in 635 cases. *JAMA* 1963; 184:11-17.
- Turkel H, Bethell FH. Biopsy of bone marrow performed by a new and simple instrument. *J Lab Clin Med* 1943; 28: 1246-1251.
- McFarland W, Dameshek W. Biopsy of bone marrow with the Vin- Silverman needle. *JAMA* 1958; 166:1464-1466.
- Silverman I. A new biopsy needle. *Am J Surg* 1938; 40:671-672.
- Conrad ME, Crosby WH. Bone marrow biopsy: modification of the Vim- Silverman needle. *J Lab Clin Med* 1961; 57: 642-654.
- Ellis LD, Jensen WN, Westerman MP. Needle biopsy of bone marrow. An experience with 1445 biopsies. *Arch Intern Med* 1964; 114:213-221.
- Miller GC, Dennis DT. Bone and marrow biopsy with saw-toothed modification of Vin- Silverman needle. *Lancet* 1968; 14:1278-1279.
- Ackermann W. Vertebral trephine biopsy. *Ann Surg* 1956; 143:373.
- Jamshidi K, Swaim WR. Bone marrow biopsy with unaltered architecture: a new biopsy device. *J Lab Clin Med* 1971; 77: 335-342.
- Inwood MJ. Jamshidi bone marrow needle modification. *J Lab Clin Med* 1975; 86:535-537.
- Islam A. A new bone marrow biopsy needle with core securing device. *J Clin Pathol* 1981; 35:359-364.
- Schajowicz F, Derqui JC. Puncture biopsy in lesions of the locomotor system. Review of results in 4050 cases, including 941 vertebral punctures. *Cancer* 1968; 21: 531-548.
- Ayala AG, Ro JY, Fanning CV, Flores JP, Yasko A. Core needle biopsy and fine needle aspiration in the diagnosis of bone and soft tissue lesions. *Hematol Oncol Clin North Am* 1995; 9:633-651.
- Ayala AG, Zornosa J. Primary bone tumors: percutaneous needle biopsy. Radiologic-Pathologic study of 222 biopsies. *Radiology* 1983; 149:675-679.
- Bishop PW, Mc Nally K, Harris M. Audit of bone marrow trephines. *J Clin Pathol* 1992; 45:1105-1108.
- Mink J. Percutaneous bone biopsy in the patient with known or suspected osseous metastases. *Radiology* 1986; 161:191-194.
- Mitsuyoshi G, Naito N, Kawai A, Kunisada T, Yoshida A, Yanai H, Dendo S, Yoshino T, Kanazawa S, Ozaki T. Accurate diagnosis of musculoskeletal lesions by core needle biopsy. *J Surg Oncol* 2006; 94:21-27.
- Altuntas AO, Slavin J, Smith PJ, Schlicht SM, Powell GJ, Ngan S, Toner G, Choong PF. Accuracy of computed tomography guided core needle biopsy of musculoskeletal tumours. *ANZ J Surg* 2005; 75:187-191.

19. Santini-Araujo E, Olvi LG, Muscolo DL, Velan O, González ML, Cabrini RL. Technical Aspects of Core Needle Biopsy and Fine Needle Aspiration in the Diagnosis of Bone Lesions. *Acta Cytologica* 2011; 55: 100-105.
20. Fernández LR, Carraro JJ. Punción aspirativa en los maxilares. *Rev Asoc Odontol Argent* 1972; 60:375-377.
21. Platt JC, Rodgers SF, Davidson D, Nelson CL. Fine needle aspiration biopsy in oral and maxillofacial surgery. *Oral Surg Oral Med Oral Pathol* 1993; 75:152-55.
22. Friedlander AH. Use of a needle biopsy in oral and maxillofacial surgery. *Oral Surg Oral Med Oral Pathol* 1976; 41:411-415.
23. Najjar TA, Gaston GW. Biopsy technique for fibro-osseous and osteolytic lesions of the jaws. *Oral Surg Oral Med Oral Pathol* 1977; 44:177-182.
24. Yeh CH¹, Yeow KM, Chu SY, Pan KT, Hung CF, Hsueh S, Su IH. Imaging findings in mandibular primitive neuroectodermal tumour: a report of a rare case and review of the literature. *Dentomaxillofac Radiol.* 2011;40:451-6
25. Larheim TA, Westesson P, Hicks DG, Eriksson L, Brown DA. Osteonecrosis of the temporomandibular joint: correlation of magnetic resonance imaging and histology. *J Oral Maxillofac Surg* 1999; 57:888-898.
26. Kerawala, CJ. Endoscopically-guided core biopsy of the condylar head. *Br J Oral Maxillofac Surg* 2008; 46:306-307.