

Factors associated to apical overfilling after a thermoplastic obturation technique – Calamus® or Guttacore®: a randomized clinical experiment

Javier L. Nino-Barrera^{1,2}, Luis F. Gamboa-Martinez¹,
Horacio Laserna-Zuluaga¹, Jessy Unapanta¹,
Daniela Hernández-Mejía¹, Carolina Olaya¹,
Diana Alzate-Mendoza¹

¹ Universidad el Bosque, Facultad de Odontología, Posgrado de Endodoncia Bogotá, Colombia.

² Universidad Nacional de Colombia, Facultad de Odontología, Bogotá, Colombia.

ABSTRACT

The aims of this study were to analyze whether age, tooth type and sex are related to radiographically visible extrusion of filling material as an unintended outcome in teeth undergoing endodontic treatment with a thermoplastic obturation technique (Calamus® or GuttaCore®) and to determine whether the presence of such overfilling is associated to postoperative pain. We selected 120 teeth with diagnoses involving vital pulp and indication for endodontic treatment. Biomechanical preparation was performed using the Protaper Next® system with X2 or X3 master apical file. Teeth were randomly divided into 2 groups (n=60). Teeth in Group 1 were filled with the Guttacore® system and teeth in Group 2 were filled with single cone technique and Calamus® obturation system. Thermoplastic obturation techniques were found to cause overfilling in 53.33% of the total

cases (64 teeth) (56.66% in Guttacore® group and 50% in the Calamus® group). Anterior teeth were found to be associated to presence of overfilling (p= 0.024) (OR = 4.35). Of the 120 teeth treated, 10 (8.33%) presented postoperative pain and radiographically visible overfilling. The association between presence of extruded filling material and mild/moderate pain was statistically significant with p = 0.002.

To conclude, endodontic thermoplastic obturation with Guttacore® and Calamus® systems are significantly associated with the probability of filling material extrusion, and overfilling is associated to postoperative pain. Anterior teeth are 4 times more likely to be overfilled with the obturation techniques tested.

Key words: Gutta-percha; Pain; Root Canal Filling Materials.

Factores asociados con la presencia de sobreobtención apical posterior a una técnica de obturación termoplástica Calamus® o Guttacore®: experimento clínico aleatorizado

RESUMEN

Los objetivos de esta investigación fueron: Analizar si factores como la edad, el tipo de diente y el género están asociados con la extrusión de material obturador radiográficamente visible como desenlace imprevisto en dientes sometidos a tratamiento endodóntico con una técnica de obturación termoplástica (Calamus® o GuttaCore®) y determinar si la presencia de esta sobreobtención está asociada con dolor posoperatorio. Se seleccionaron 120 dientes con diagnósticos que implicaban pulpa vital y con indicación de tratamiento de endodoncia. La preparación biomecánica se llevó a cabo con el sistema ProtaperNext® con lima apical principal X2 o X3. Los dientes se dividieron aleatoriamente de la siguiente forma (n=60): El grupo 1 se obturó con el sistema Guttacore® y el grupo 2 se obturó con una técnica de obturación de cono único y el sistema de obturación Calamus®. Se observó que las técnicas de obturación termoplástica generaron sobreobtención en 53.33% del total (64 dientes), 56.66% se presentaron en el grupo de obturación

con Guttacore® y 50% en el grupo de la técnica con el sistema Calamus®. Se encontró que los dientes anteriores presentaron asociación con la presencia de sobreobtención (p= 0.024) (OR=4.35). De los 120 dientes tratados, 10 (8.33 %) presentaron dolor posoperatorio y sobreobtención radiográficamente visible. La asociación entre la presencia de extrusión de material de obturación y dolor leve-moderado fue estadísticamente significativa con un valor p= 0.002.

Como conclusión las técnicas de obturación termoplástica en endodoncia Guttacore® y el sistema Calamus® están asociadas significativamente con la probabilidad de extrusión de material obturador y dicha sobreobtención está asociada con dolor posoperatorio, los dientes anteriores presentan 4 veces más riesgo de sobreobtención con las técnicas de obturación utilizadas.

Palabras clave: Gutapercha; Dolor; Materiales para obturación del conducto radicular.

INTRODUCTION

The aim of root canal obturation is to prevent pathogenic microorganisms from invading and recolonizing the root canal by after its preparation and biomechanical cleaning by sealing it hermetically, both apically and laterally, with biocompatible materials^{1,2}. Three-dimensional obturation techniques helped by sealers are used to reduce the presence of voids in the obturation and achieve appropriate fit and adherence to root canal walls^{1,3-5}.

The concept of 3-D root canal filling with warm gutta-percha condensation technique was introduced by Schilder in 1967⁶ and has developed over time with the advent of devices facilitating it^{1,3,4}. These new techniques enable root canals to be filled with thermoplasticized gutta-percha, which favors 3-D filling⁷.

Among recently developed techniques for dispensing thermoplasticized gutta-percha inside the root canal with the aim of facilitating and optimizing vertical condensation are Calamus[®] (Dentsply[®], Maillefer[®], Switzerland), which works as an integrated system with “Downpack” for the apical third creating an apical plug and “Backfill” for the middle and coronal thirds, providing 3-D filling throughout the root canal^{5, 8, 9}, and theGuttacore[®] system, (Dentsply[®] Tulsa Dental Specialties, Tulsa, OK, USA), which uses a thermally stable cross-linked gutta-percha core which enables the material to preserve its properties during and after the procedure, thereby achieving 3-D obturation¹⁰⁻¹².

Overfilling has been defined as obturation which reaches the radiographic apex and extrudes within the periapical tissue¹³ and has been classified as a procedural accident¹⁴.

Extrusion of filling material has also been called “apical puff”, and is radiographically visible as a small quantity of sealer protruding through the apical foramen, sometimes with remains of gutta-percha^{15, 16}.

With regard to the influence of factors such as tooth type or age on presence of apical overfilling, AlRahabi reports that upper molars are the teeth most likely to have accidental apical overfilling, showing that the type of tooth does influence whether or not there is apical extrusion of filling material. However that study considered lateral condensation techniques, not modern thermoplasticized gutta-percha techniques¹⁷. With regard to age, a higher number of endodontic failures has

been reported in patients aged 41 to 50 years, although the cause of endodontic failure has not been specified as overfilling¹⁸.

Tennert et al. report presence of apical extrusion of filling material in 80% with Thermafil[®] and 42% with warm vertical compaction technique⁴. However, to date there is no study in the literature evaluating presence of overfilling *in vivo* with the technological development of the techniques used by Tennert et al.⁴, including thermoplasticized gutta-percha obturation systems such as Calamus[®] and Guttacore[®].

Prognosis for endodontic treatments with overfilling of material (sealer and/or gutta-percha) has been a subject of controversy. Ricucci et al. report that the type of extruded sealer does not affect treatment prognosis and that overfilling has better prognosis if the tooth does not have preoperative apical lesion¹⁹. Sadaf et al. report low association between overfilling and postoperative pain (3.3%) and between pain and sealer extrusion (26.7%)²⁰.

Swartz et al.² report 63.41% success rate in overfilled teeth, which is significantly lower than the 89.77% observed for teeth with adequate obturation length. Marquis et al.²¹ report 86% success rate for cases without extruded sealer and 73% success rate with extruded sealer. In a meta-analysis to determine optimal obturation length, Schaeffer et al. report that teeth without overfilling have significantly better prognosis than overfilled teeth²².

Similarly, the extrusion of obturation material has been reported as a factor that delays bone repair in teeth with periapical pathology²³. It has been reported that apical extrusion of sealer can damage the nerve structures in the periapical tissue, altering the sensitivity of the nerves involved²⁴⁻²⁷.

The Thermafil[®] system, which is the predecessor of Guttacore[®], has been reported to have higher risk of extrusion of filling material compared to the cold lateral condensation technique, and this extrusion is associated with the occurrence of postoperative pain 24 to 48 hours after the procedure²⁸. This might be explained by apical overfilling stimulating and activating sensory neurons, which are related to the manifestation of acute postoperative pain in the treated tooth.

According to the above, postoperative pain may be associated to overfilling in root canal treatment; however, there is no report on how these symptoms are related to extrusion of filling material as a result of thermoplastic techniques such as Calamus[®] and

Guttacore®. Neither are there any reports on the association between overfilling with Calamus® and Guttacore® techniques and factors such as age, tooth type or sex.

The aims of this study were thus to analyze whether age, tooth type and sex are associated with radiographically visible extrusion of filling material as an unintended outcome in teeth subjected to endodontic treatment with thermoplastic obturation (Calamus® or Guttacore®) and to determine whether the presence of overfilling is associated to postoperative pain.

MATERIALS AND METHODS

This was a randomized clinical experiment. It was approved by the Research and Ethics Committee of Universidad el Bosque (Bogotá, Colombia), during an Institutional Ethics Committee session on December 4, 2014.

The study considered patients who visited the post-graduate endodontics clinic at Universidad El Bosque (Bogotá Colombia) with indication for root canal treatment between March 1, 2015 and January 30, 2016. (Fig.1)

Patients were informed and invited to participate in the research project. They participated after completing the regulatory clinical history used at Universidad El Bosque (Bogota, Colombia) and completing the informed consent for the clinical study. Sample size was calculated probabilistically using the asymptotic normal method with type I error 0.05 and type II error 0.20. Sample size was determined as 60 teeth per group, including a 20% dropout rate.

The study analyzed 120 teeth in patients aged 18 to 60 years of both sexes who had been referred to the post-graduate endodontics clinic at Universidad El Bosque (Bogota, Colombia).

Inclusion criteria were teeth with vital pulp with indication for endodontic treatment, with formed apex, and for which during biomechanical preparation, maximum master apical file diameter was X2 or X3 (Protaper Next®).

Exclusion criteria were teeth diagnosed with apical periodontitis, teeth with

open apex or which during biomechanical preparation presented a master apical file larger than X2 or X3 (Protaper Next®).

Biomechanical preparation protocol for teeth using the Protaper Next® system included the following steps: local anesthetic block with 2% lidocaine and 1:80,000 epinephrine; opening and shaping the access cavity with high-speed handpiece, round diamond bur and endo-Z bur; locating root canal entrance with endodontic probe. The operating field was completely isolated with rubber sheet. Root canal apical patency was verified with a size 10 file, working length was determined with a Root ZX II® apex locator (J. Morita®) and confirmed with a conductometry radiograph.

Biomechanical preparation was performed with the Protaper Next® system, and for the selected teeth it was confirmed that they presented master apical file X2 (025.06) or X3 (030.07) by continuing with pecking motion until working length was reached, irrigating constantly with 5.25% sodium hypochlorite. Lastly, the final irrigation protocol was performed, which consisted of drying the canal with sterile paper points, irrigating with 17% EDTA for one minute, drying the canal again with sterile paper points and irrigating with 5.25% sodium hypochlorite, and drying the canal once again with sterile paper points. The manufacturer's instructions were followed for root canal obturation: working length was confirmed, the canal was coated with 1:1 Top Seal® cement²⁹

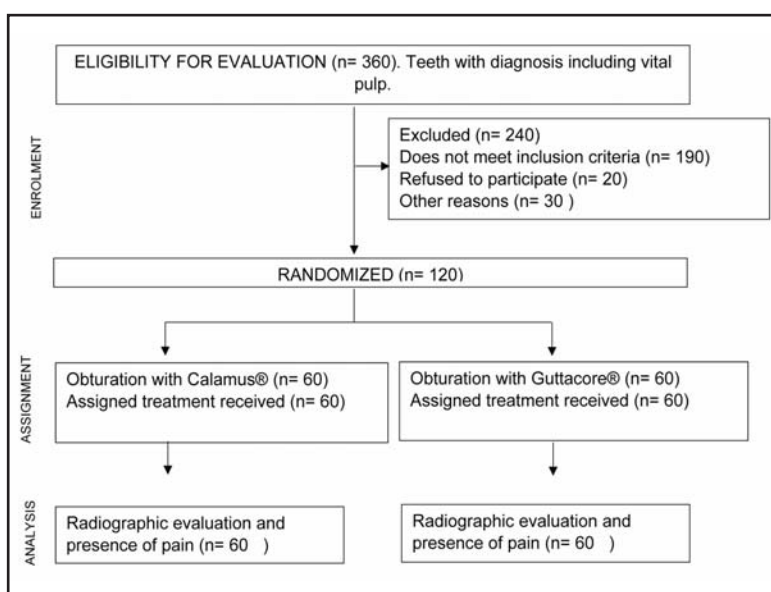


Fig. 1: Distribution and randomization of the groups.

with a Protaper Next® system (Dentsply®) X2 or X3 paper point to working length³⁰.

Group 1 was filled with the Guttacore® system (Dentsply®) and Group 2 was filled with a hybrid obturation technique using Protaper Next® single cone (Dentsply®) and obturation technique with Calamus® thermoplasticized gutta-percha (Dentsply®), following the manufacturer's instructions. Lastly, a final radiograph was taken.

In order to standardize the digital periapical radiographs (initial, conductometry, conometry and final radiograph) a mold was made with heavy silicone on which to position the sensor and hold it in fixed position, allowing reproducibility in the angle of the radiographs.

Presence of overfilling or extrusion of filling material was evaluated in the final radiograph by an endodontics specialist (JN) with 16 years' experience, who was blinded to the filling procedure performed on each patient.

All patients had a follow-up visit 24 hours after the endodontic procedure, in order to establish whether there was postoperative pain. If there was, it was managed with occlusal adjustment and analgesic³¹. Intensity and presence of pain were measured on a visual analog scale (VAS) with values ranging from 1 mm to 170 mm, classified as follows: 0 mm to 54 mm mild pain, 54 mm to 114 mm moderate pain and 114 mm to 170 mm severe pain³².

In order to ensure that the process would be unpredictable, subjects were assigned randomly to the study groups by means of numbers generated using the STATA® software RALLOC command and sealed in opaque, sequentially numbered envelopes. Following diagnosis and signature of informed consent, envelopes were opened and the

procedure performed at the post-graduate Endodontics Clinic at Universidad del Bosque (Bogotá, Colombia) by post-graduate residents under teacher supervision. Under no circumstances was patient assignment to one of the experimental groups known prior to endodontic treatment. The endodontist who read and evaluated the radiographs was blinded.

Statistical analysis

Pearson's chi-square test was used for differences between proportions. Subsequently, bivariate tests were performed to determine relationships between dependent variables (presence of overfilling) and independent variables (age, sex, tooth type and filling system). The quantitative-qualitative nature of the study variables was taken into account.

Multivariate analysis was adjusted according to socio demographic variables, confounding variables and possible interaction, in order to model the effect of different risk factors on presence of overfilling and determine whether potential differences between experimental groups are maintained after controlling the various factors associated to the presence of the study event. As the outcomes were dichotomic (presence or absence of overfilling or extrusion of filling material), a logistic regression analysis was performed.

A p-value < 0.05 was determined in all cases. All statistical analyses were performed on STATA®.

The information obtained was entered directly into an EXCEL® electronic database. Names were kept separate from the rest of the information, which was stored under unique identifying numbers. STATA® files were created to analyze all the information in the registers and individual results.

Table 1: Baseline characteristics of patients and teeth in the study. There is no significant difference in distribution of patients and teeth between groups.

	Calamus® (n=60)	Guttacore® (n=60)	Total (n=120)	P value =
Age (years)	51.43±11.72	50.7±10.27	51.06±10.98	0.258
Sex				0.073
Female	38 (63.33%)	48 (80%)	86 (71.67)	
Male	22 (36.66%)	12 (20%)	34 (28.33)	
Tooth type				0.086
Anterior	18 (30%)	8 (13.33%)	26 (21.67%)	
Premolars	17 (28.33%)	21 (35%)	38 (31.67%)	
Molars	25 (41.67%)	31 (51.67%)	56 (46.67%)	

RESULTS

Table 1 shows the baseline characteristics of the study subjects and their distribution into two experimental groups. Pearson’s chi-square test found no significant difference between groups, i.e. the distribution of age ($p = 0.258$), sex ($p = 0.073$) and tooth type ($p = 0.086$) are similar in both experimental groups, and therefore did not affect the results of the study.

Tables 2 and 3 show presence of extruded filling material with the Calamus® and Guttacore® techniques. Both techniques produced extruded sealer. Extruded sealer was present in 53.33% (64 teeth) overall. There was extrusion in 56.66% of teeth treated with Guttacore® and 50% of teeth treated with Calamus®, with no significant

difference between groups ($p = 0.583$), although frequency was higher for Guttacore® (Table 3).

Out of the total patients treated with either of the two thermoplasticized gutta-percha techniques (Calamus® or Guttacore®), 8.33% (10 teeth) presented mild/moderate postoperative pain, while 91.6% presented no pain. No statistically significant difference in postoperative pain was found between filling techniques ($p = 0.509$), although it was higher for Calamus® (Table 4).

Since all teeth presenting pain also presented extruded filling material, when Pearson’s chi-square test (Fisher’s exact test) was applied, it found significant association between presence of extruded filling material and mild/moderate pain ($p = 0.002$) (Table 5).

For this study, teeth were classified as anterior, premolars and molars^{17,33}. Significant association was found between presence of extruded filling material and anterior teeth ($p = 0.024$). There was higher incidence of overfilling (76.92%) in anterior teeth than in premolars (47.37%) or molars (46.43%) (Table 6).

Logistic regression analysis on the factors associated to presence of extruded filling material shows anterior teeth as a variable with statistically

Table 2: Presence of apical extrusion with Calamus® and Guttacore®.

Extrusion of filling material	Frequency	Percentage
Yes	64	53.33%
No	56	46.67%
Total	120	100%

Table 3: Apical puff with Calamus® and Guttacore®. There is no significant difference between obturation techniques (P = 0.58).

Technique	Presence of apical puff					
	Yes		No		Total	
	N	%	N	%	n	%
CALAMUS®	30	50%	30	50%	60	100%
GUTTACORE®	34	56.66%	26	43.33%	60	100%
TOTAL	64	53.33%	56	46.66%	120	100%

Table 5: Significant association (Pr = 0.002) between presence of extruded filling material and mild/moderate postoperative pain.

Pain	Apical puff		
	No	Yes	Total
No	56 (50.91%)	54 (49.09%)	110 (100%)
Yes	0 (0.0%)	10(100%)	10(100%)
Total	56(46.67%)	64(53.33%)	120(100%)

Table 4: Mild/moderate postoperative pain. There is no significant difference in presence of pain between obturation techniques (P = 0.509).

Technique	Postoperative pain					
	Yes		No		Total	
	N	%	N	%	n	%
CALAMUS®	6	10%	54	90%	60	100%
GUTTACORE®	4	6.67%	56	93.3%	60	100%
TOTAL	10	8.33%	110	91.6%	120	100%

Table 6: Presence of apical puff according to tooth type. There is significant association between anterior teeth and extruded filling material (P = 0.024).

Tooth	Apical puff		
	No	Yes	Total
Anterior	6 (23%)	20 (76.92%)	26 (100%)
Premolars	20(52.63%)	18(47.37%)	38(100%)
Molars	30(53.57%)	26(46.43%)	56(100%)
Total	56(46.67%)	64(53.33%)	120(100%)

significant association in the raw model (OR 3.70; $P = 0.01$). In the model adjusted with the variables sex, age and filling system, the same factor (anterior teeth) was the only one with statistically significant association ($p = 0.01$) with OR 4.35, which means that the risk of extruded filling material from a root canal in an anterior tooth is 4 times higher than in a premolar or molar.

DISCUSSION

This randomized clinical experiment was conducted to evaluate what factors could influence the presence of accidental apical overfilling or extrusion of sealer. Following randomization, a statistical verification confirmed that factors were distributed between groups in similar proportions, enabling dismissal of the possibility of results being affected by any imbalance. This is important to note because apical foramen diameter varies according to age³⁴ and differs between anterior and posterior teeth³⁵, so confirmation of similar distribution between groups provides reliability to the results.

Overall, with the Calamus[®] and Guttacore[®] obturation techniques used in this study there was extrusion of filling material in 53.33%. This value differs from Tennert et al.⁴, who report 80% extrusion of material with Thermafil[®] and 42% with a vertical condensation filling technique⁴. In addition, the present study found no significant difference in extrusion of filling material between the two techniques. The difference between Tennert et al. and the current study may be due to study methodological design. Tennert et al. conducted a retrospective study with little control over inclusion criteria, whereas the current study was prospective, with randomized distribution into groups, and controlled both the procedures performed and the inclusion criteria.

De Chevigny et al.³⁶ found 53% extrusion of filling material in a sample grouping the Toronto study phases 1 to 4, which is in agreement with the 53.33% reported in the current study. However, De Chevigny et al.³⁶ used lateral condensation and vertical condensation filling techniques, so clearly, filling material extrusion or overfilling may occur regardless of the filling technique and without the possibility of being predicted with total certainty¹⁴, although the outcome is generally functional^{19, 21, 36}, so that it may be considered an accident with good prognosis.

Said good prognosis may be owed to the periapical tissue's tolerance to the cytotoxicity of the filling material (gutta-percha and sealer)^{37, 38}, although if filling material extrudes and affects neighboring anatomical structures, it may lead to consequences which could cause patient discomfort^{16, 24-27, 39}. Here, it is important to stress that it is not possible to predict how much filling material (sealer or gutta-percha) will extrude or how far it will reach^{14, 39}, in addition to which extruded material can only be detected radiographically after the obturation has been completed. It is therefore important to endeavor to keep the obturation material within the root canal, limiting extrusion to what it really is: an accident with good prognosis, not an aim of the obturation.

Wong et al.⁴⁰ conducted a meta-analysis observing overfilling and postoperative pain in teeth with root canals filled with Thermafil[®] system, finding postoperative pain in 24%, higher than the 8.33% found in the current study. Wong et al.⁴⁰ claim that postoperative pain was due to the extrusion of filling material⁴⁰. This explanation may also apply in the current study, which found that all teeth presenting postoperative pain also had extruded filling material.

AlRahabi¹⁷ report average overfilling of 44.15% in molars (62.5% in upper molars and 25.8% in lower molars), similar to the overall 46.43% found for molars in the current study. However, for anterior teeth, AlRahabi, report 16.25% (20% for upper incisors and 12.5% for lower incisors), which is much lower than the 76.92% found in the current study. Differences in treatment protocols may explain this inconsistency between results. These differences include that the current study determined working length with an apex locator (Root ZX II[®] J Morita[®].) and confirmed it radiographically, while AlRahabi¹⁷ only took a conductometry radiograph, and that in AlRahabi the root canal treatments were performed by undergraduate fourth or fifth year students, while in the current study they were performed by postgraduate students of endodontics. The statistically significant association found between extrusion of filling material and anterior teeth may be explained by two reasons: (a) as has been reported previously, it is easier to fill anterior than posterior teeth,^{14, 17} and (b) the difference in the diameter of the apical foramen between anterior and posterior teeth³⁵. Statistically significant association between extrusion of filling material and anterior teeth has not

been reported previously in the literature, so anterior teeth should be taken into account as a risk factor for extruded filling material. Special care should thus be taken to maintain a stable apical limit during biomechanical preparation of anterior teeth to prevent extrusion of filling material.

Within the limitations of this study, it may be concluded that the endodontic thermoplastic filling

techniques with Guttacore® and the Calamus® system are significantly associated to the probability of filling material extrusion. In this regard, there is no difference between techniques and overfilling is associated with mild/moderate post-operative pain. Anterior teeth are 4 times more likely to be overfilled than premolars and molars with these filling techniques.

ACKNOWLEDGMENTS

We thank Universidad El Bosque and its directorship of post-graduate degrees for making this study possible by means of financial support received through the Sixth Internal Call for research and technological innovation funding projects.

CORRESPONDENCE

Dr. Javier Niño-Barrera
Calle 135 # 58B -21 Interior 2 Apartamento 302
Bogotá, Colombia
javinino40@gmail.com

REFERENCES

- Tomson RM, Polycarpou N, Tomson PL. Contemporary obturation of the root canal system. *Br Dent J* 2014;216: 315-322.
- Swartz DB, Skidmore AE, Griffin JA, Jr. Twenty years of endodontic success and failure. *J Endod* 1983;9:198-202.
- Farias AB, Pereira KF, Beraldo DZ, Yoshinari FM, Arashiro FN, Zafalon EJ. Efficacy of three thermoplastic obturation techniques in filling oval-shaped root canals. *Acta Odontol Latinoam* 2016;29:76-81.
- Tennert C, Jungback IL, Wrbas KT. Comparison between two thermoplastic root canal obturation techniques regarding extrusion of root canal filling—a retrospective in vivo study. *Clin Oral Investig* 2013;17:449-454.
- Gupta R, Dhingra A, Panwar NR. Comparative Evaluation of Three Different Obturating Techniques Lateral Compaction, Thermafil and Calamus for Filling Area and Voids Using Cone Beam Computed Tomography: An Invitro study. *J Clin Diagn Res* 2015;9:ZC15-17.
- Schilder H. Filling root canals in three dimensions. *Dent Clin North Am* 1967;7:23-744.
- Brothman P. A comparative study of the vertical and the lateral condensation of gutta-percha. *J Endod* 1981;7:27-30.
- Ruddle CJ. Filling root canal systems: the Calamus 3-D obturation technique. *Dent Today* 2010;29:76, 78-81.
- Jindal D, Sharma M, Raisingani D, Swarnkar A, Pant M, Mathur R. Volumetric analysis of root filling with cold lateral compaction, Obtura II, Thermafil, and Calamus using spiral computerized tomography: An In vitro Study. *Indian J Dent Res* 2017;28:175-180.
- Zogheib C, Hanna M, Pasqualini D, Naaman A. Quantitative volumetric analysis of cross-linked gutta-percha obturators. *Ann Stomatol (Roma)* 2016;7:46-51.
- Schafer E, Schrenker C, Zupanc J, Burklein S. Percentage of Gutta-percha Filled Areas in Canals Obturated with Cross-linked Gutta-percha Core-carrier Systems, Single-Cone and Lateral Compaction Technique. *J Endod* 2016; 42:294-298.
- Marques-Ferreira M, Abrantes M, Ferreira HD, Caramelo F, Botelho MF, Carrilho EV. Sealing efficacy of system B versus Thermafil and Guttacore obturation techniques evidenced by scintigraphic analysis. *J Clin Exp Dent* 2017; 9:e56-e60.
- Kandemir Demirci G, Caliskan MK. A Prospective Randomized Comparative Study of Cold Lateral Condensation Versus Core/Gutta-percha in Teeth with Periapical Lesions. *J Endod* 2016;42:206-210.
- Mozayeni MA, Asnaashari M, Modaresi SJ. Clinical and Radiographic Evaluation of Procedural Accidents and Errors during Root Canal Therapy. *Iran Endod J* 2006;1:97-100.
- Koch K, Brave D. A new endodontic obturation technique. *Dent Today* 2006;25:102, 104-107.
- Morse DR. Infection-related mental and inferior alveolar nerve paresthesia: literature review and presentation of two cases. *J Endod* 1997;23:457-460.
- AlRahabi MK. Evaluation of complications of root canal treatment performed by undergraduate dental students. *Libyan J Med* 2017;12:1345582.
- Iqbal A. The Factors Responsible for Endodontic Treatment Failure in the Permanent Dentitions of the Patients Reported to the College of Dentistry, the University of Aljouf, Kingdom of Saudi Arabia. *J Clin Diagn Res* 2016; 10:ZC146-148.
- Ricucci D, Rocas IN, Alves FR, Loghin S, Siqueira JF, Jr. Apically Extruded Sealers: Fate and Influence on Treatment Outcome. *J Endod* 2016;42:243-249.
- Sadaf D, Ahmad MZ. Factors associated with postoperative pain in endodontic therapy. *Int J Biomed Sci* 2014;10:243-247.
- Marquis VL, Dao T, Farzaneh M, Abitbol S, Friedman S. Treatment outcome in endodontics: the Toronto Study. Phase III: initial treatment. *J Endod* 2006;32:299-306.
- Schaeffer MA, White RR, Walton RE. Determining the optimal obturation length: a meta-analysis of literature. *J Endod* 2005;31:271-274.
- Sarin A, Gupta P, Sachdeva J, Gupta A, Sachdeva S, Nagpal R. Effect of Different Obturation Techniques on the Prognosis of Endodontic Therapy: A Retrospective Comparative Analysis. *J Contemp Dent Pract* 2016;17:582-586.
- Rosen E, Goldberger T, Taschieri S, Del Fabbro M, Corbella S, Tsesis I. The Prognosis of Altered Sensation after

- Extrusion of Root Canal Filling Materials: A Systematic Review of the Literature. *J Endod* 2016;42:873-879.
25. Nitzan DW, Stabholz A, Azaz B. Concepts of accidental overfilling and overinstrumentation in the mandibular canal during root canal treatment. *J Endod* 1983;9:81-85.
 26. Blanas N, Kienle F, Sandor GK. Injury to the inferior alveolar nerve due to thermoplastic gutta percha. *J Oral Maxillofac Surg* 2002;60:574-576.
 27. Blanas N, Kienle F, Sandor GK. Inferior alveolar nerve injury caused by thermoplastic gutta-percha overextension. *J Can Dent Assoc* 2004;70:384-387.
 28. Alonso-Ezpeleta LO, Gasco-Garcia C, Castellanos-Cosano L, Martin-Gonzalez J, Lopez-Frias FJ, Segura-Egea JJ. Postoperative pain after one-visit root-canal treatment on teeth with vital pulps: comparison of three different obturation techniques. *Med Oral Patol Oral Cir Bucal* 2012; 17:e721-727.
 29. Top Seal Instructions for use Maillefer Instruments SA CH -1338 Ballaigues Switzerland [Internet]2014. URL: http://www.dentsplymaillefer.com/wp-content/uploads/2015/Dentsply/Obturation/Ciments/TOPSEAL/produit49_EN.pdf.
 30. DENTSPLY Tulsa Dental Specialties DI, Inc. Dentsply Sirona, Inc. GuttaCore® Crosslinked Gutta-Percha Core Obturators Directions for Use. Step-by-Step Instructions, 7 Drying the Canal and Applying Sealer. 608 Rolling Hills Dr. Johnson City, TN 37604: 2017. p. pag 7. URL: www.dentsplysirona.com;
 31. Aminoshariae A, Kulild JC, Donaldson M, Hersh EV. Evidence-based recommendations for analgesic efficacy to treat pain of endodontic origin: A systematic review of randomized controlled trials. *J Am Dent Assoc* 2016;147:826-839.
 32. Mehrvarzfar P, Esnashari E, Salmanzadeh R, Fazlyab M, Fazlyab M. Effect of Dexamethasone Intraligamentary Injection on Post-Endodontic Pain in Patients with Symptomatic Irreversible Pulpitis: A Randomized Controlled Clinical Trial. *Iran Endod J* 2016;11:261-266.
 33. Hale R, Gatti R, Glickman GN, Opperman LA. Comparative analysis of carrier-based obturation and lateral compaction: a retrospective clinical outcomes study. *Int J Dent* 2012; 2012:954675.
 34. Fang Y, Wang X, Zhu J, Su C, Yang Y, Meng L. Influence of Apical Diameter on the Outcome of Regenerative Endodontic Treatment in Teeth with Pulp Necrosis: A Review. *J Endod* 2018;44:414-431.
 35. Vertucci FJ. Root canal morphology and its relationship to endodontic procedures. *Endod Topics* 2005;10:3-29.
 36. de Chevigny C, Dao TT, Basrani BR, Marquis V, Farzaneh M, Abitbol S, Friedman S. Treatment outcome in endodontics: the Toronto study—phase 4: initial treatment. *J Endod* 2008;34:258-263.
 37. Scotti R, Tiozzo R, Parisi C, Croce MA, Baldissara P. Biocompatibility of various root canal filling materials ex vivo. *Int Endod J* 2008;41:651-657.
 38. Tavares T, Soares IJ, Silveira NL. Reaction of rat subcutaneous tissue to implants of gutta-percha for endodontic use. *Endod Dent Traumatol* 1994;10:174-178.
 39. Yamaguchi K, Matsunaga T, Hayashi Y. Gross extrusion of endodontic obturation materials into the maxillary sinus: a case report. *Oral Surg Oral Med Oral Pathol Oral Radiol Endod* 2007;104:131-134.
 40. Wong AW, Zhang S, Li SK, Zhang C, Chu CH. Clinical studies on core-carrier obturation: a systematic review and meta-analysis. *BMC Oral Health* 2017;17:167.