

Unprepared areas and centralization of oval canals prepared with WaveOne Gold or XP-endo Shaper: microcomputed tomographic analyses

Marília FV Marceliano-Alves¹, Vivian Ronquete¹, Thais MC Coutinho¹, Tchilalo Boukpassi², Amanda LF Salvioni¹, Paula ASR Goulart¹, Ana GS Limoeiro³, Flavio RF Alves⁴, Pablo A Amoroso-Silva⁴

1. Universidade Iguazu, Departamento de Endodontia, Nova Iguazu, Rio de Janeiro, Brazil

2. Université Paris Cité, Laboratory of Orofacial Pathologies, Imaging and Biotherapies, Laboratoire d'Excellence INFLAMEX, URP 2496, Montrouge, France

3. Private Practice, Jequié, Brazil.

4. Universidade Grande Rio, Programa de pós-graduação em Odontologia, Duque de Caxias, Brazil

ABSTRACT

Current instrumentation systems cannot fully prepare oval root canal systems. This may cause accumulation of hard tissue debris and fail to eliminate bacteria from areas inaccessible to instrumentation, which could perpetuate periapical inflammation and jeopardize the success of endodontic treatment. **Aim:** To evaluate the performance of two endodontic systems in oval canals by investigating the changes in volume, unprepared areas, and centering ability of XP-endo Shaper (XPS) and WaveOne Gold (WOG) in oval canals using microcomputed tomography (micro-CT). **Materials and Method:** Thirty mandibular canines were scanned before and after preparation with WOG (25/.07 and 35/.06) or XPS (30/.01) to evaluate the volume, surface area, and canal centralization at 4 mm and 10 mm from the apical foramen. **Results:** Volume and surface area increased significantly after preparation with both systems ($p < 0.05$). However, no significant difference was observed in the unprepared areas, regarding either the entire canal (26.21% for WOG and 30.10% for XPS), or the apical segment (18.82% for WOG and 14.63% for XPS) ($p > 0.05$). **Conclusions:** Both systems maintained canal centralization, with no difference between them. XPS and WOG had similar shaping abilities in the mandibular canine, but left almost one third of the unprepared areas.

Keywords: endodontics - root canal preparation - X ray microtomography.

To cite:

Marceliano-Alves MFV, Ronquete V, Coutinho TMC, Boukpassi T, Salvioni AL F, Goulart PASR, Limoeiro AGS, Alves FRF, Amoroso-Silva PA. Unprepared areas and centralization of oval canals prepared with WaveOne Gold or XP-endo Shaper: microcomputed tomographic analyses. Acta Odontol Latinoam. 2023 Dec 31;36(3):177-182. <https://doi.org/10.54589/aol.36/3/177>

Corresponding Author:

Marília F Marceliano-Alves
mmarceliano@hotmail.com

Received: September 2023.

Accepted: November 2023.

Áreas não preparadas e centralização de canais ovais preparados com WaveOne Gold ou XP-endo Shaper: análises tomográficas microcomputadorizadas

RESUMO

Os sistemas de instrumentação atuais são incapazes de preparar completamente os sistemas de canais radiculares do canal oval, o que pode levar ao acúmulo de detritos de tecido duro e manter micro-organismos em áreas inacessíveis à instrumentação. Essas bactérias poderiam perpetuar a inflamação periapical e comprometer o sucesso do tratamento endodôntico. **Objetivo:** Para avaliar o comportamento de dois sistemas endodônticos em canais ovais, esse estudo investigou as alterações no volume, áreas não preparadas e capacidade de centralização do XP-endo Shaper (XPS) e do WaveOne Gold (WOG) em canais ovais usando microtomografia computadorizada (micro-CT). **Material e métodos:** Trinta caninos inferiores foram escaneados antes e depois do preparo com WOG (25/.07 e 35/.06) ou XPS (30/.01) para avaliar o volume, a área de superfície e a centralização do canal a 4 mm e 10 mm do forame apical. **Resultados:** O volume e a área de superfície aumentaram significativamente após o preparo com ambos os sistemas ($p < 0,05$). No entanto, não foram observadas diferenças significativas nas áreas não preparadas, não apenas em todo o canal (26,21% para WOG e 30,10% para XPS), mas também no segmento apical (18,82% para WOG e 14,63% para XPS) ($p > 0,05$). **Conclusão:** Ambos os sistemas mantiveram a centralização do canal, sem diferenças entre eles. O XPS e o WOG tiveram habilidades de modelagem semelhantes no canino mandibular, mas deixaram quase um terço das áreas do canal sem preparo.

Palavras-chave: endodontia - preparo do canal radicular - microtomografia por raio-X.



This work is licensed under a Creative Commons Attribution-NonCommercial 4.0 International License

INTRODUCTION

The main goal of infected root canal treatment is maximum intracanal microbial reduction, primarily by irrigation, chemical debridement, and mechanical action of instruments¹, to allow healing of the periradicular tissues. However, these steps can be challenging due to the complexity of the root canal anatomy².

Mandibular canines usually have high incidence of oval root canals³, which various instrumentation systems cannot clean completely⁴, leaving unprepared areas^{4,5}. In addition, anatomic complexity may complicate infection control by allowing accumulation of hard tissue debris and failing to eliminate bacteria from inaccessible areas to instrumentation^{2,4,5}. Remaining microorganisms can perpetuate periapical inflammation and jeopardize the success of endodontic treatment⁶. Therefore, instruments with different kinematics and heat treatment have been developed to treat root canals with complex anatomy, such as oval root canals⁶. The WaveOne Gold (WOG) (Dentsply-Sirona, Ballaigues, Switzerland) is a reciprocating single-file system made of a heat-treated metal alloy (M-wire). It has a parallelogram-shaped cross-section with two cutting edges, resulting in one or two points of contact between the instrument and the dentin walls. These features provide increased flexibility and improved cyclic fatigue resistance compared to conventional NiTi alloys^{7,8}.

The XP-endo Shaper (XPS) system (30/0.1) (FKG Dentaire SA, La Chaux-de-Fonds, Switzerland) uses the Max-Wire alloy (Brasseler, Savannah, GA). It is a single-use file with rotating, eccentric motion to treat the canal three-dimensionally, and it responds to temperature variations. It has a triangular cross-section and a booster tip with six sharp edges and a reduced diameter that facilitates advancement into the apical region of the root canal while maintaining the original curvature. According to the manufacturer, it can expand from its original taper of 0.1 to 0.4 at the end of preparation, enabling extended horizontal action. The manufacturer states two mechanisms of action: agitation of the irrigation fluid, which increases cleaning power, and mechanical contact with the inner walls of the canal, which increases the removal of microorganisms by reaching areas of the canal not reached by the usual instruments.

Microcomputed tomography (micro-CT) is a nondestructive method that provides high-resolution,

three-dimensional images for assessment of internal tooth anatomy, and considered the gold standard for assessment of the root canal preparation^{2,10}.

The ability of WOG and XPS to clean and disinfect canines has been studied previously, but to our knowledge, this is the first work comparing centering ability¹¹. The aim of this study was to evaluate the changes in volume and area, the percentage of unprepared canal areas and the centering ability of the XPS and WOG systems in oval root canals, using micro-CT.

MATERIAL AND METHOD

The project for this study was submitted to and approved by the Institutional Research Ethics Committee (CAAE: 53653621.2.0000.8044).

Sample selection and initial micro-CT scanning

G*Power 3.1 software (Heinrich Heine College, Duesseldorf, Germany) was used to calculate power with $\beta = 95\%$ and $\alpha = 5\%$, and a t test for independent samples was applied. The ideal sample size for each group was determined to be at least 10 teeth. Five additional samples per group were added to compensate for possible loss.

Thirty mandibular canines with moderately curved roots (10° to 20°) were selected from a pool of 432 teeth. All specimens were scanned in micro-CT scanner (SkyScan 1173, Bruker, Kontich, Belgium) at 70 kV and 114 mA, with a 1-mm-thick aluminum filter, exposure time 320 milliseconds, pixel size $12.1 \mu\text{m}$, rotation step 0.8° , and rotation 360° along the vertical axis. The files were reconstructed into a three-dimensional data set using the program NRecon v1.6.1.0 (Bruker micro-CT), with beam hardening correction of 50%, ring artifact correction of 10, and smoothing of 5. The volume of interest extended from the cemento-enamel junction to the root apex, resulting in the acquisition of 600 to 700 axial slices per sample.

CTAn v.1.14.4 and CTVol v.2.2.1 software (Bruker Micro-CT) were used to evaluate the morphology of the root canal in terms of volume, surface area, and 3D configuration. Teeth were paired based on the anatomical similarities of preoperative canal volume, canal length of approximately 12 mm, canal surface area, and 3D configuration. One specimen from each pair was randomly assigned to each of the 2 experimental groups ($n=15$): XPS and WOG.

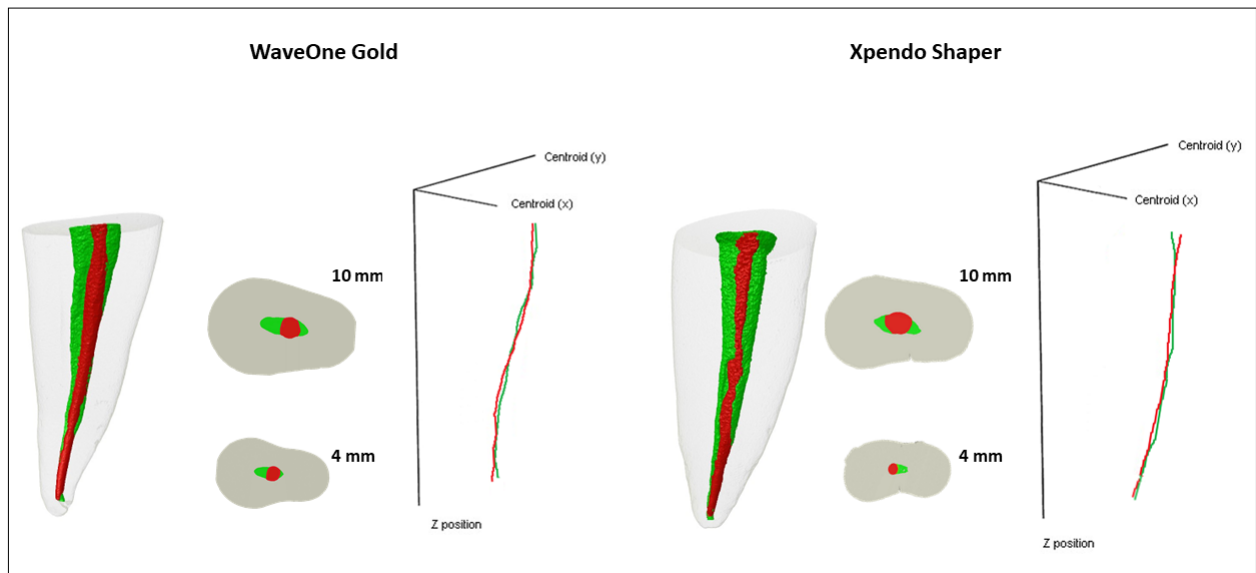


Fig. 1: Representative images show the unprepared areas highlighted in green. Diagram shows the centralization after preparation (red) compared to the centralization of the sound canal (Z-axis-green) along the entire canal (10 mm segment).

Root canal preparation

The canals were rinsed with 1 mL of 2.5% NaOCl and examined with a #10 K manual file (Dentsply-Maillefer, Ballaigues, Switzerland) until the tip of the instrument was visible in the apical foramen under 8 \times magnification. The working length (WL) was determined to be 1.0 mm based on this measurement. To simulate the resistance imposed by the periodontal ligament and allow the formation of vapor lock, the apexes were sealed with Top Dam (FGM, Joinville, Brazil).

The XPS 30/.01 instrument (promoting a 30/.04 preparation) was used with a 6:1 contra-angle handpiece coupled to an electric motor (VDW Silver, VDW GnbH, Munich, Germany) set at 800 rpm and 100 g/cm. The instrument was used with gentle strokes of 5 to 7 mm to WL.

The WOG system was driven by an electric motor (VDW GmbH, Munich, Germany). The preparation started with the primary instrument (25/.07) and was completed with the medium instrument (35/.06) in reciprocating motion with gentle apical pressure in slow in and out movements with slight apical advancements of 2-3 mm to the WL.

All procedures were performed in a cabinet maintained at 37 °C by a heater (800-Heater; PlasLabs, Lansing, USA) to simulate body temperature. For both groups, after 3 instrumentation cycles (1 cycle equal to 3 back-and-forth movements), the canal was flushed with 1 mL of 2.5% NaOCl, patency was

checked with a #10 K file, and the instrument was cleaned with sterile gauze. Irrigation was performed with a 30G NaviTip needle (Ultradent Products Inc, South Jordan, USA) 3 mm from WL using a 5 mL disposable syringe. The irrigant was simultaneously aspirated at the canal opening with a cannula connected to a 90 mL/s suction pump.

Micro-CT images and analyses after instrumentation

After instrumentation, all teeth were rescanned in a micro-CT (Skyscan 1173, Bruker) under the same acquisition and reconstruction parameters. The volume (mm³) and surface area (mm²) at 4 mm (apical canal) and 10 mm (entire canal) from the apical foramen were calculated using Image J 1.50d software (National Institutes of Health, Bethesda, MD). The same software was used to evaluate the amount of unprepared root canal areas (%) by calculating the number of static voxels by the total number of voxels on the canal surface and expressing it as a percentage. CTVol v.2.3.1 software (Bruker, micro-CT) was used to define a color-coded pattern for the canal templates (green for before instrumentation and red for after instrumentation) (Fig. 1). This enabled comparison of the recorded pre- and postoperative scan canal models. Centering ability was assessed by the center of gravity of the canal (Z-axis) compared to before and after preparations along the entire canal (10 mm segment).

Statistical analysis

Statistical analysis was performed using R16 software. Normality of the data was checked using the Shapiro-Wilk test. The Mann-Whitney test was used to compare the differences between the XPS and WOG groups, both for the entire canal and for the apical canal. The Wilcoxon test was used for within-group analyses. A significance level of 5% ($p < 0.05$) was considered for all tests.

RESULTS

Volume and area increased significantly after preparation with both systems ($p < 0.05$). However, no significant difference was observed in the unprepared areas, either in the entire canal (26.21% for WOG and 30.10% for XPS), or in the apical segment (18.82% for WOG and 14.63% for XPS) ($p > 0.05$) (Table 1). Both systems maintained the centralization (centroid analysis) of the canal with no difference between them ($p > 0.05$) (Table 1).

Table 1. Variations of canal parameters after canal preparation with the tested systems.

| Micro-CT canal parameters | WaveOne Gold mean (SD) | XP-endo Shaper mean (SD) |
|---------------------------------|------------------------|--------------------------|
| 4 mm | | |
| Surface area (mm ²) | 18.82 (21.27) | 14.63 (11.93) |
| Volume (mm ³) | 5.19 (8.47) | 3.28 (11.36) |
| Unprepared areas (%) | 14.19 (17.63) | 12.51 (9.08) |
| 10 mm | | |
| Surface area (mm ²) | 32.02 (33.60) | 28.75 (48.48) |
| Volume (mm ³) | 16.88 (14.82) | 13.07 (16.96) |
| Unprepared areas (%) | 26.21 (29.05) | 30.10 (19.29) |

DISCUSSION

This multi-analytic study of oval canals evaluated changes in volume and area, as well as the percentage of unprepared areas and the centralization of root canal preparation with XPS and WOG. Separate analyses were performed for the entire canal and the apical canal to better understand the shaping ability of these two new systems. Strict tooth pairing was performed based on micro-CT anatomical parameters to minimize selection bias, even when the same tooth type was used, because anatomical variability within the same group of teeth, including mandibular canines, can be significant¹².

Cleaning and shaping oval canals is considered challenging in clinical practice^{1,2}. Root canal

preparation is affected not only by the characteristics of the instruments, but also by the variability of dental anatomy. In mandibular canines, canals may have varying lengths and cross-sectional shapes throughout the root, but they are generally oval in the cervical and middle thirds, whereas they may be more round or slightly oval in the apical third⁴. The major challenges in preparing these teeth include maintaining the original canal shape, apical foramen and curvature, and preparing them evenly in all directions¹³⁻¹⁵.

Unprepared canal areas and their potential impact on endodontic prognosis are a matter of concern. A histologic and scanning electron microscopy study showed that unprepared areas still contain residual pulp and/or bacterial cells despite an extensive irrigation protocol¹. Instruments with expansion capacity, such as the XPS, have been proposed to reduce unprepared canal areas, especially in oval canals. The rotary eccentric motion combined with contraction of the instrument at body temperature has the potential to contact more areas than conventional rotary/reciprocating instruments, as shown by some studies on distal roots of mandibular molars^{8,16} and mandibular canines¹⁷. However, these results were not confirmed in the present study, in which the WOG system showed similar results. Whereas in the previously mentioned study, XPS was compared to the Mtwo 35.05 instrument in canines, in the present study, XPS was compared to the WOG 35.06 instrument. This difference in taper could explain the similarity of the unprepared areas between the systems tested. In addition, the choice of the final apical instrument in our study was based on the median apical diameters (0.30 to 0.40 mm) reported in previous studies¹⁸.

According to other studies, XPS and WOG perform better in round or small oval canals^{2,8,17}. In contrast, some studies have reported that unprepared canal surfaces after instrumentation can range from 10.9% to 59.6%, especially in long oval canals^{8,19,20}.

The current study found that unprepared canal surfaces as a percentage of total canal length were 26% for WOG and 30% for XPS, suggesting that XPS cannot reach all areas of the oval root canal despite its properties^{8,21,22}. Therefore, in teeth with complex canal anatomy, including oval canals, additional strategies are recommended to optimize root canal shaping, such as circular filling with Hedström files or ultrasonic tips^{23,24}.

Apical transportation after canal preparation depends

on the degree and radius of curvature, canal anatomy, and the instrument used. Some accidents may weaken and tear the dentin wall, compromising success²⁵. In the present study, no significant deviation was observed for either system, both of which were similar. This result is consistent with another study on mesial canals of mandibular molars²⁶.

The tested instruments produced well-centered preparations, which can be attributed to their

mechanical behavior as a result of their good flexibility provided by the alloys of which they are manufactured⁸.

CONCLUSIONS

XPS and WOG had similar shaping abilities in the oval canals of mandibular canines and maintained the centralization of the canals. However, almost one-third of the oval canal areas remained unprepared.

CONFLICT OF INTEREST

The authors declare no potential conflicts of interest regarding the research, authorship, and/or publication of this article.

FUNDING

The study was supported by grants from Fundação Carlos Chagas Filho de Amparo à Pesquisa do Estado do Rio de Janeiro (FAPERJ) (E-26/202.729/2019) and Conselho Nacional de Desenvolvimento Científico e Tecnológico (CNPq) (200280/2022-8), Brazilian Governmental Institutions.

REFERENCES

1. Siqueira JF, Pérez AR, Marceliano-Alves MF, Provenzano JC, et al. What happens to unprepared root canal walls: a correlative analysis using micro-computed tomography and histology/scanning electron microscopy. *Int Endod J*. 2018;51:501-8. <https://doi.org/10.1111/iej.12753>
2. Lacerda MFLS, Marceliano-Alves MF, Pérez AR, Provenzano JC, et al. Cleaning and Shaping Oval Canals with 3 Instrumentation Systems: A Correlative Micro-computed Tomographic and Histologic Study. *J Endod*. 2017;43:1878-84. <https://doi.org/10.1016/j.joen.2017.06.032>
3. Wu MK, R'oris A, Barkis D, Wesselink PR. Prevalence and extent of long oval canals in the apical third. *Oral Surg Oral Med Oral Pathol Oral Radiol Endod*. 2000;89:739-43. <https://doi.org/10.1067/moe.2000.106344>
4. Versiani MA, Leoni GB, Steier L, De-Deus G, et al. Micro-computed tomography study of oval-shaped canals prepared with the self-adjusting file, Reciproc, WaveOne, and ProTaper universal systems. *J Endod*. 2013;39:1060-6. <https://doi.org/10.1016/j.joen.2013.04.009>
5. Peters OA, Laib A, Göhring TN, Barbakow F. Changes in root canal geometry after preparation assessed by high-resolution computed tomography. *J Endod*. 2001;27:1-6. <https://doi.org/10.1097/00004770-200101000-00001>
6. Versiani MA, Alves FRF, Andrade-Junior C V, Marceliano-Alves MF, et al. Micro-CT evaluation of the efficacy of hard-tissue removal from the root canal and isthmus area by positive and negative pressure irrigation systems. *Int Endod J*. 2016;49:1079-87. <https://doi.org/10.1111/iej.12559>
7. Özyürek T. Cyclic Fatigue Resistance of Reciproc, WaveOne, and WaveOne Gold Nickel-Titanium Instruments. *J Endod*. 2016;42:1536-9. <https://doi.org/10.1016/j.joen.2016.06.019>
8. Poly A, Marques F, Moura Sassone L, Karabucak B. The shaping ability of WaveOne Gold, TRUShape and XP-endo Shaper systems in oval-shaped distal canals of mandibular molars: A microcomputed tomographic analysis. *Int Endod J*. 2021;54:2300-6. <https://doi.org/10.1111/iej.13625>
9. Gavini G, Santos M Dos, Caldeira CL, Machado ME de L, et al. Nickel-titanium instruments in endodontics: a concise review of the state of the art. *Braz Oral Res*. 2018 18;32(suppl 1):e67. <https://doi.org/10.1590/1807-3107bor-2018.vol32.0067>
10. Peters OA, Arias A, Paqué F. A Micro-computed Tomographic Assessment of Root Canal Preparation with a Novel Instrument, TRUShape, in Mesial Roots of Mandibular Molars. *J Endod*. 2015;41:1545-50. <https://doi.org/10.1016/j.joen.2015.06.007>
11. Krokidis A, Nicola B, Antonio C, Panopoulos P. Comparison of Two Reciprocating and Anatomical Single File Techniques in Cleaning Oval Anatomies. *Iran Endod J*. 2023;18:41-6. <https://doi.org/10.22037/2Fiej.v18i1.33623>
12. Versiani MA, Pécora JD, Sousa-Neto MD. Microcomputed tomography analysis of the root canal morphology of single-rooted mandibular canines. *Int Endod J*. 2013;46:800-7. <https://doi.org/10.1111/iej.12061>
13. Versiani MA, Carvalho KKT, Mazzi-Chaves JF, Sousa-Neto MD. Micro-computed Tomographic Evaluation of the Shaping Ability of XP-endo Shaper, iRaCe, and EdgeFile Systems in Long Oval-shaped Canals. *J Endod*. 2018;44:489-95. <https://doi.org/10.1016/j.joen.2017.09.008>
14. Ronquete V, Martin AS de, Zuim K, Coutinho TM de C, et al. Microtomographic Evaluation of Canal Centralization and Dentine Removal after Canal Preparation with Two Rotary Systems: HyFlex EDM and ProTaper Next. *Eur J Dent*. 2022;16:663-8. <https://doi.org/10.1055/s-0041-1739440>
15. Pacheco-Yanes J, Gazzaneo I, Campello AF, Marceliano-Alves MF, et al. Planned Apical Preparation Using Cone-Beam Computed Tomographic Measures: A Micro-Computed Tomographic Proof of Concept in Human Cadavers. *J Endod*. 2022;48:280-6. <https://doi.org/10.1016/j.joen.2021.11.016>
16. Poly A, Tseng WJL, Marques F, Setzer FC, et al. Micro-Computed Tomographic Analysis of the Shaping Ability of XP-Endo Shaper in Oval-Shaped Distal Root Canals of Mandibular Molars. *Eur Endod J*. 2021;6:271-7. <https://doi.org/10.14744/ej.2021.44153>
17. Xavier SR, de Lima CO, Marceliano-Alves MFV, Lacerda

- MFLS, et al. Shaping ability of two root canal instrumentation systems in oval-shaped canals: A microcomputed tomography study. *Aust Endod J* 2021;47:252-9. <https://doi.org/10.1111/aej.12469>
18. Green D. A stereomicroscopic study of the root apices of 400 maxillary and mandibular anterior teeth. *Oral Surg Oral Med Oral Pathol.* 1956;9:1224-32. [https://doi.org/10.1016/0030-4220\(56\)90192-X](https://doi.org/10.1016/0030-4220(56)90192-X)
 19. Paqué F, Balmer M, Attin T, Peters OA. Preparation of oval-shaped root canals in mandibular molars using nickel-titanium rotary instruments: a micro-computed tomography study. *J Endod.* 2010;36:703-7. <https://doi.org/10.1016/j.joen.2009.12.020>
 20. Siqueira Junior JF, Rôças I das N, Marceliano-Alves MF, Pérez AR, et al. Unprepared root canal surface areas: causes, clinical implications, and therapeutic strategies. *Braz Oral Res.* 2018 18;32(suppl 1):e65. <https://doi.org/10.1590/1807-3107bor-2018.vol32.0065>
 21. Velozo C, Silva S, Almeida A, Romeiro K, et al. Shaping ability of XP-endo Shaper and ProTaper Next in long oval-shaped canals: a micro-computed tomography study. *Int Endod J.* 2020;53:998-1006. <https://doi.org/10.1111/iej.13301>
 22. Thomas JP, Lynch M, Paurazas S, Askar M. Micro-computed Tomographic Evaluation of the Shaping Ability of WaveOne Gold, TRUShape, EdgeCoil, and XP-3D Shaper Endodontic Files in Single, Oval-shaped Canals: An In Vitro Study. *J Endod.* 2020;46:244-251.e1. <https://doi.org/10.1016/j.joen.2019.11.001>
 23. Gazzaneo I, Amoroso-Silva P, Pacheco-Yanes J, Alves FRF, et al. Disinfecting and Shaping Type I C-shaped Root Canals: A Correlative Micro-computed Tomographic and Molecular Microbiology Study. *J Endod.* 2021;47:621-30. <https://doi.org/10.1016/j.joen.2020.11.007>
 24. Amoroso-Silva P, Alcalde MP, Hungaro Duarte MA, De-Deus G, et al. Effect of finishing instrumentation using NiTi hand files on volume, surface area and uninstrumented surfaces in C-shaped root canal systems. *Int Endod J.* 2017;50:604-11. <https://doi.org/10.1111/iej.12660>
 25. Bürklein S, Mathey D, Schäfer E. Shaping ability of ProTaper Next and BT-RaCe nickel-titanium instruments in severely curved root canals. *Int Endod J.* 2015;48:774-81. <https://doi.org/10.1111/iej.12375>
 26. Pérez Morales M de LN, González Sánchez JA, Olivieri JG, Elmsmari F, et al. Micro-computed Tomographic Assessment and Comparative Study of the Shaping Ability of 6 Nickel-Titanium Files: An In Vitro Study. *J Endod.* 2021;47:812-9. <https://doi.org/10.1016/j.joen.2020.12.021>