

**CASE REPORT****ISOLATED ABDUCENS NERVE PALSY TREATED BY IMMUNOADSORPTION IN A PATIENT WITH DIARRHEA-ASSOCIATED HEMOLYTIC UREMIC SYNDROME***PARÁLISIS OCULAR AISLADA DEL SEXTO PAR CRANEAL TRATADA CON INMUNOADSORCIÓN EN UN PACIENTE CON SÍNDROME URÉMICO HEMOLÍTICO ASOCIADO A DIARREA*Sibel Ersan<sup>1</sup>, Sevda Uckun Kocak<sup>2</sup>

1) Nephrology Department, Izmir Tepecik Training and Research Hospital, Izmir, Turquía

2) Internal Medicine Department, Izmir Tepecik Training and Research Hospital, Izmir, Turquía

Rev Nefrol Dial Traspl. 2018;38(2):134-8

**ABSTRACT**

Shiga toxin-producing *Escherichia coli* (STEC) that causes a prodromal hemorrhagic enteritis is the main cause of hemolytic uremic syndrome (HUS) particularly in pediatric patients. It is characterized by acute kidney injury with microangiopathic hemolytic anemia and thrombocytopenia. The kidney and brain are the two major target organs, and neurological involvement is the most frequent cause of mortality. The time delay between bloody diarrhea and neurological symptoms ranges from few days to a month. Neurological disorders include disturbances in cognitive functions, focal neurological signs, epileptic seizures, myoclonus and neuropsychiatric symptoms. Cerebral magnetic resonance imaging reveals various patterns of hyperintensities distributed through cerebral matter or may be totally normal even when the patient has severe neurological involvement. Electroencephalography usually shows generalized or focal slowing of the background activity, spikes or sharp waves despite being normal in around 20% of patients.

We present here an adult male patient referred to our center with requirement of hemodialysis due to diarrhea-associated HUS complicated by acute kidney injury. Later during the course of plasma

exchange therapy the patient developed an isolated abducens nerve palsy. Complete renal recovery was achieved by plasma exchange therapy but abducens palsy remedied rescue introduction of immunoglobulin G (IgG) depletion by immunoadsorption.

**KEYWORDS:** abducens palsy; hemolytic uremic syndrome; immunoadsorption; *Escherichia coli*; neurological syndrome; Shiga toxin

**RESUMEN**

*Escherichia coli*, productor de toxina Shiga (STEC), que causa una enteritis hemorrágica en fase prodrómica, es la principal causa del síndrome urémico hemolítico (SUH), particularmente, en pacientes pediátricos. Se caracteriza por una lesión renal aguda con anemia hemolítica microangiopática y trombocitopenia. El riñón y el cerebro son los dos órganos principales a los que ataca, y la afectación neurológica es la causa más frecuente de mortalidad. El tiempo que transcurre entre la aparición de diarrea sangui-nolenta y los síntomas neurológicos varía entre pocos días y un mes. Los trastornos neurológicos incluyen alteraciones en las funciones cognitivas, signos neurológicos focales, ataques epilép-

ticos, mioclonías y síntomas neuropsiquiátricos. La resonancia magnética de cerebro revela varios patrones de hiperintensidades distribuidas a través de la materia cerebral o puede ser totalmente normal incluso si el paciente tiene un compromiso neurológico severo. El electroencefalograma generalmente muestra una disminución generalizada o focal de la actividad de fondo, picos u ondas agudas, a pesar de ser normal en alrededor del 20 % de los pacientes.

Presentamos aquí un paciente adulto de sexo masculino, derivado a nuestro centro para ser tratado con hemodiálisis debido a SUH asociado a diarrea, complicado por insuficiencia renal aguda. Luego, durante el transcurso de la terapia de intercambio de plasma, el paciente desarrolló una parálisis ocular aislada del sexto par craneal. Se logró una recuperación renal completa por medio de la plasmáferesis; no obstante, la parálisis del nervio motor ocular externo mejoró con la disminución de la inmunoglobulina G (IgG) mediante el tratamiento de rescate por inmunoadsorción.

**PALABRAS CLAVE:** parálisis del nervio abducens; síndrome urémico hemolítico; inmunoadsorción; *Escherichia coli*; síndrome neurológico; toxina Shiga

## INTRODUCTION

Haemolytic uraemic syndrome (HUS) is defined as the triad of anaemia, thrombocytopenia, and acute kidney injury (AKI) and is most often associated with a prodromal haemorrhagic enteritis caused by Shiga toxin (Stx)-producing *Escherichia coli* (STEC).<sup>(1-2)</sup> It is predominantly a disease of children and the majority of outbreaks have been linked to *E. Coli* serotype O157:H7 although sporadic cases and outbreaks associated with unusual *E. coli* strains and other microorganisms such as pneumococci are emerging.<sup>(3-4)</sup> The disease is rare in adults however during the northern German outbreak of 2011, 88% of the patients who developed HUS were adults.<sup>(5)</sup>

The main target organs of Stx-mediated damage are the kidney and the central nervous

system. Renal involvement is usually amenable to treatment with temporary renal replacement therapy. By contrast neurological involvement, less common in STEC-HUS patients, is relatively treatment-resistant and comprises the most frequent cause of acute mortality.<sup>(3,6)</sup> Neurological disturbances range from limited neurologic defects including headache, diplopia, and aphasia to more severe manifestations such as altered consciousness, seizures, stroke, coma, cortical blindness and hemiparesis.<sup>(2,4,6-8)</sup> We present an adult male with diarrhea-associated HUS (D<sup>+</sup> HUS) who developed isolated unilateral abducens nerve palsy in the course of the disease. Complete recovery was achieved by institution of IgG depletion through immunoadsorption.

## CASE HISTORY

A 32-year-old previously healthy male presented to another hospital with nausea and vomiting, and bloody diarrhea lasting more than a week. He underwent colonoscopy to rule out inflammatory bowel disease, and was put on both corticosteroid and antimicrobial therapy. He lost more than 10% of his weight in a week.

After six days following bloody diarrhea he developed acute kidney injury with anuria and referred to our hospital. On admission the patient was fully conscious with primary complaints of shortness of breath, abdominal cramps and moderate headache. He claimed that the frequency of watery and bloody diarrhea had decreased significantly. But micturition could not be achieved. His blood pressure was 150/95 mmHg, heart rate 104/minutes, respiratory rate 24/minutes, body temperature 37.2°C, and SpO<sub>2</sub> 94% on room air. Physical examination revealed few crackles at lung bases on auscultation, and abdominal tenderness but no sign of peritoneal irritation. The rest of the physical examination was normal. A complete blood count revealed leucocytosis (14100/mm<sup>3</sup>), anemia (hemoglobin 9,8 g/dL) and thrombocytopenia (84000/mm<sup>3</sup>). Laboratory findings were as follows: bicarbonate (HCO<sub>3</sub>) 14 mEq/l, and venous pH 7.26, serum creatinine 14.5 mg/dl, and lactic dehydrogenase (LDH) 1349 IU/L. Acute kidney injury

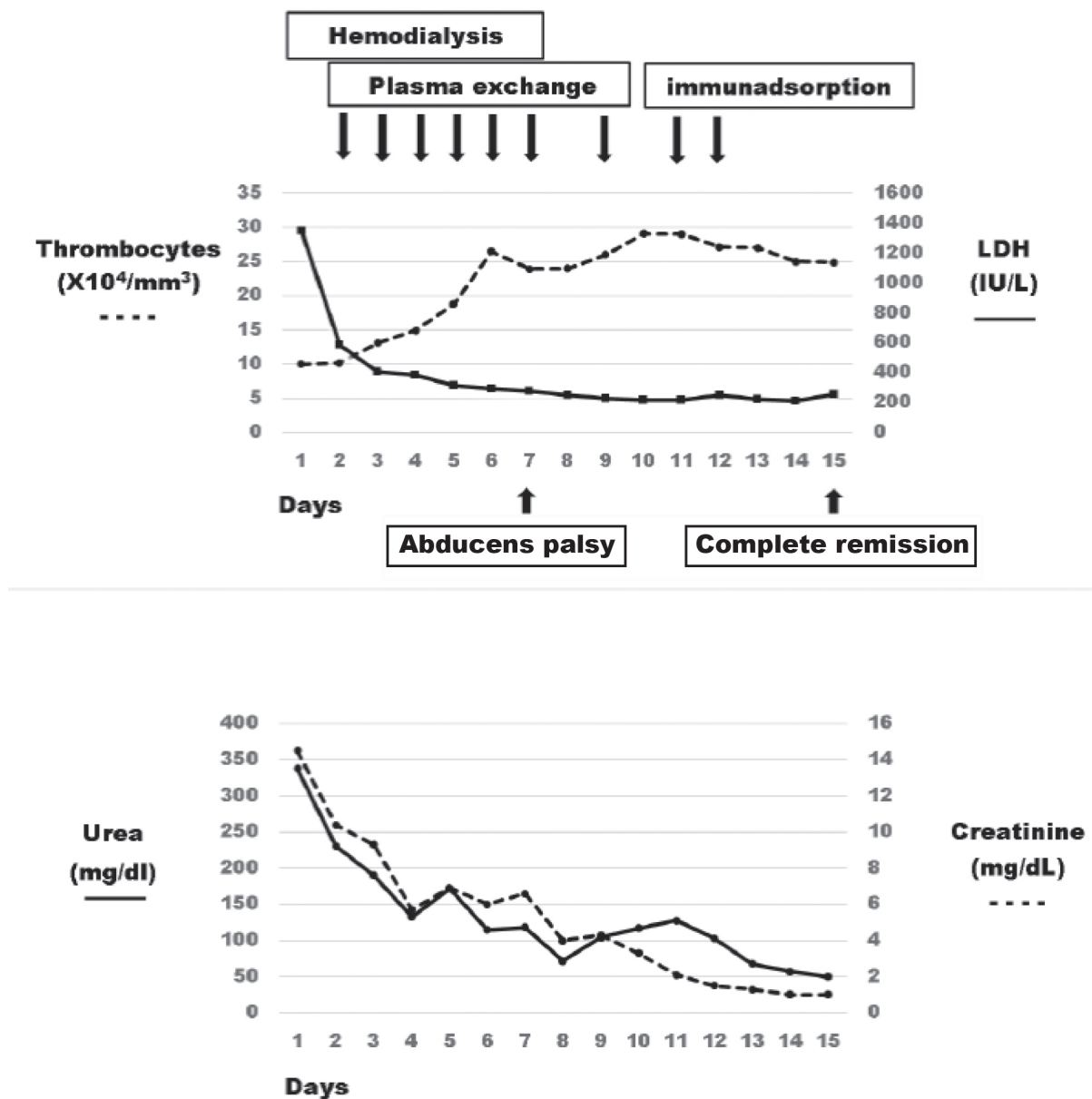
with thrombocytopenia and the presence of schistocytes on the peripheral blood smear led to the diagnosis of HUS. Both hemodialysis and plasma-exchange (PE) with fresh frozen plasma replacement in amount of 1.2 times the calculated plasma volume was initiated consecutively. As he was given corticosteroids in another center before admission to our hospital we continued that therapy as an oral prednisolone (1 mg/kg).

Microscopic examination of the stool indicated erythrocytes and few leucocyte, but fecal culture on sorbitol-MacConkey agar couldn't detect

neither *E. Coli* O157:H7 strains nor other pathogens. Due to lack of commercially available Shiga toxin detection assay in our center we could not test for the presence of the toxin.

A plasma sample collected prior to initiation of PE showed a disintegrin-like and metalloproteinase with thrombospondin type 1 motifs member 13 (ADAMTS13) activity level of 74.95% and the sample was negative for ADAMTS13 inhibitor. These findings excluded the diagnosis of thrombotic thrombocytopenic purpura (TTP). The patient's clinical course is summarized in **Figure 1**.

**Figure 1.** Clinical and biochemical course of the patient



On the seventh day of admission the patients presented polyuria and didn't need further hemodialysis. Thrombocytes were normalized, creatinine and LDH levels gradually decreased. While the patient was under treatment by plasmapheresis presented diplopia and vertigo. Neurological examination revealed isolated right abducens nerve palsy. The biochemistry results did not explain his symptoms nor did his cerebral magnetic resonance imaging (MRI). Following two further sessions of plasmapheresis there was no improvement in his neurological defect. We put the patient on IgG immunodepletion by immunoadsorption. His condition improved dramatically by two sessions of immunoadsorption with complete neurological recovery.

## DISCUSSION

The neurological involvement in the course of D<sup>+</sup>-HUS occurs in 20-25% of patients and is the most threatening complication of the disease. Although the mechanism is not fully understood, Stx-induced vascular injury, endothelial dysfunction, hypertension, and metabolic/electrolyte disturbances can be involved.<sup>(6)</sup> Abducens palsies often have been associated with other neurological disturbances during the course of HUS.<sup>(9-10)</sup> Isolated bilateral abducens palsies had been reported previously in a pediatric case of E.Coli 0157:H7-associated HUS.<sup>(11)</sup> They appeared concurrently with renal dysfunction in that case, and spontaneous complete recovery of the right and the left abducens palsies ensued within 48 and 96 hours (h), respectively.

The patient presented here had isolated unilateral abducens palsy that developed during renal recovery while the patient was on plasma exchange therapy. Although the patient had an episode of hypertension prior to development of abducens palsy, this was not thought to be the only causative factor because of the lack of any other hypertensive related neurological disturbances, and the occurrence of neurological manifestation when the patient had stable normal blood pressure. Secondary immune responses emerging during the course of disease, and formation of

Stx-anti-Stx IgG immune complexes, resulting in activation of thrombocytes and leucocytes have been proposed as pathogenic mechanisms as well.<sup>(8,12)</sup> As seen in 2011 outbreak of HUS in Germany IgG immunodepletion by immunoadsorption effectively improved neurological disturbances. This finding and the characteristic time-span of neurological complications suggested that antibodies generated to causative organism and/or to toxin contributes to pathogenesis.<sup>(8)</sup>

In the case presented we could not detect the toxin, however data show that unlike the E.Coli O157:H7 serotype the O104:H4 strain does not release Stx after incubation with antibiotics.<sup>(13)</sup> Development of abducens palsy 11 days after onset of enteritis and prompt recovery with rescue immunoadsorption in our case also suggests a secondary IgG response (**Figure 1**). Immunoadsorption has been postulated to be more effective than plasma exchange in these situations because it effectively removes IgGs and hence establishes a favorable gradient that enables redistribution of interstitial IgG into plasma. By contrast plasma exchange does not establish such a gradient as IgG-containing plasma replenishes the amount removed.

In conclusion late-onset neurological manifestations, postulated to be immune-mediated, may occur in D<sup>+</sup>-HUS. Isolated unilateral abducens palsy is an example of such neurological manifestation that responds strikingly to IgG removal by immunoadsorption.

**Conflicto de intereses:** Los autores declaran no poseer ningún interés comercial o asociativo que presente un conflicto de intereses con el trabajo presentado.

## BIBLIOGRAFÍA

- 1) Petruzzello-Pellegrini TN, Marsden PA. Shiga toxin-associated hemolytic uremic syndrome: advances in pathogenesis and therapeutics. *Curr Opin Nephrol Hypertens*. 2012;21(4):433-40.
- 2) Tarr PI, Gordon CA, Chandler WL. Shiga-toxin-

- producing *Escherichia coli* and haemolytic uraemic syndrome. *Lancet*. 2005;365(9464):1073-86.
- 3) Magnus T, Röther J, Simova O, Meier-Cillien M, Repenthin J, Möller F, et al. The neurological syndrome in adults during the 2011 northern German *E. coli* serotype O104:H4 outbreak. *Brain*. 2012;135(Pt 6):1850-9.
  - 4) Nathanson S, Kwon T, Elmaleh M, Charbit M, Launay EA, Harambat J, et al. Acute neurological involvement in diarrhea-associated hemolytic uremic syndrome. *Clin J Am Soc Nephrol*. 2010;5(7):1218-28.
  - 5) Frank C, Werber D, Cramer JP, Askar M, Faber M, an der Heiden M, et al. Epidemic profile of Shiga-toxin-producing *Escherichia coli* O104:H4 outbreak in Germany. *N Engl J Med*. 2011;365(19):1771-80.
  - 6) Trachtman H, Austin C, Lewinski M, Stahl RA. Renal and neurological involvement in typical Shiga toxin-associated HUS. *Nat Rev Nephrol*. 2012;8(11):658-69.
  - 7) Siegler RL. The hemolytic uremic syndrome. *Pediatr Clin North Am*. 1995;42(6):1505-29.
  - 8) Greinacher A, Friesecke S, Abel P, Dressel A, Stracke S, Fiene M, et al. Treatment of severe neurological deficits with IgG depletion through immunoadsorption in patients with *Escherichia coli* O104:H4-associated haemolytic uraemic syndrome: a prospective trial. *Lancet*. 2011;378(9797):1166-73.
  - 9) Hahn JS, Havens PL, Higgins JJ, O'Rourke PP, Estroff JA, Strand R. Neurological complications of hemolytic-uremic syndrome. *J Child Neurol*. 1989;4(2):108-13.
  - 10) Sheth KJ, Swick HM, Haworth N. Neurological involvement in hemolytic-uremic syndrome. *Ann Neurol*. 1986;19(1):90-3.
  - 11) Durkan A, Menascu S, Langlois V. Isolated abducens nerve palsy in hemolytic uremic syndrome. *Pediatr Nephrol*. 2004;19(8):915-6.
  - 12) Mistry B, Kimmel PL, Hetzel PC, Phillips TM, Braden GL. The role of circulating immune complexes and biocompatibility of staphylococcal protein A immunoadsorption in mitomycin C-induced hemolytic uremic syndrome. *Am J Kidney Dis*. 2004;44(4):e50-8.
  - 13) Corogeanu D, Willmes R, Wolke M, Plum G, Utermöhlen O, Krönke M. Therapeutic concentrations of antibiotics inhibit Shiga toxin release from enterohemorrhagic *E. coli* O104:H4 from the 2011 German outbreak. *BMC Microbiol*. 2012;12:160.

---

Recibido en su forma original: 20 de febrero de 2018

En su forma en corregida: 15 de marzo de 2018

Aceptación final: 26 de marzo de 2018

Dr. Sibel Ersan

Nephrology Department, Izmir Tepecik Training and Research Hospital, Izmir, Turquía

e-mail: ersansibel1@gmail.com