Diagnosis of Coronary Artery Bypass Graft In-Stent Restenosis with 64-Row Detector Tomography

VLADIMIR MENDOZA-RODRÍGUEZ[1], LUIS R. LLERENA[2], FRANCISCO CABRERA-TOLEDO[1]

Male patient, aged 57, ex smoker and hyperlipidemic, with surgical revascularization in 1995 (two bypasses): Saphenous vein graft to the left anterior descending (LDA) artery and to the right coronary artery (RCA). In March 2007, this patient was admitted due to typical angina; he was performed invasive coronary angiography, and was diagnosed with graft occlusion in RCA, and significant graft stenosis in LDA, in which he was implanted a non-drug-coated stent of 3.5 × 3 mm, resulting in successful outcome with TIMI 3 flow. A month later, he presented atypical chest pain with no changes in ECG; he was performed coronary angiography by multislice computed tomography (MSCT) with a 64-slice Somatom Sensation Cardiac, Siemens, and it revealed a permeable stent and very good flow. Six months later, he is attended in the emergency room with angor at moderate efforts (functional class II-III of NYHA). An angiography by MSCT was performed, which revealed focal in-stent restenosis of saphenous vein graft to LDA (Figure 1 A, B and C); an invasive angiography confirmed the diagnosis (Figure 1 D) and he was immediately performed balloon angioplasty (4 × 20 mm) (Figure 1 E), resulting in successful outcome with TIMI 3 flow (Figure 1 F). Further evolution was satisfactory and patient was discharged with medical treatment and outpatient follow-up.

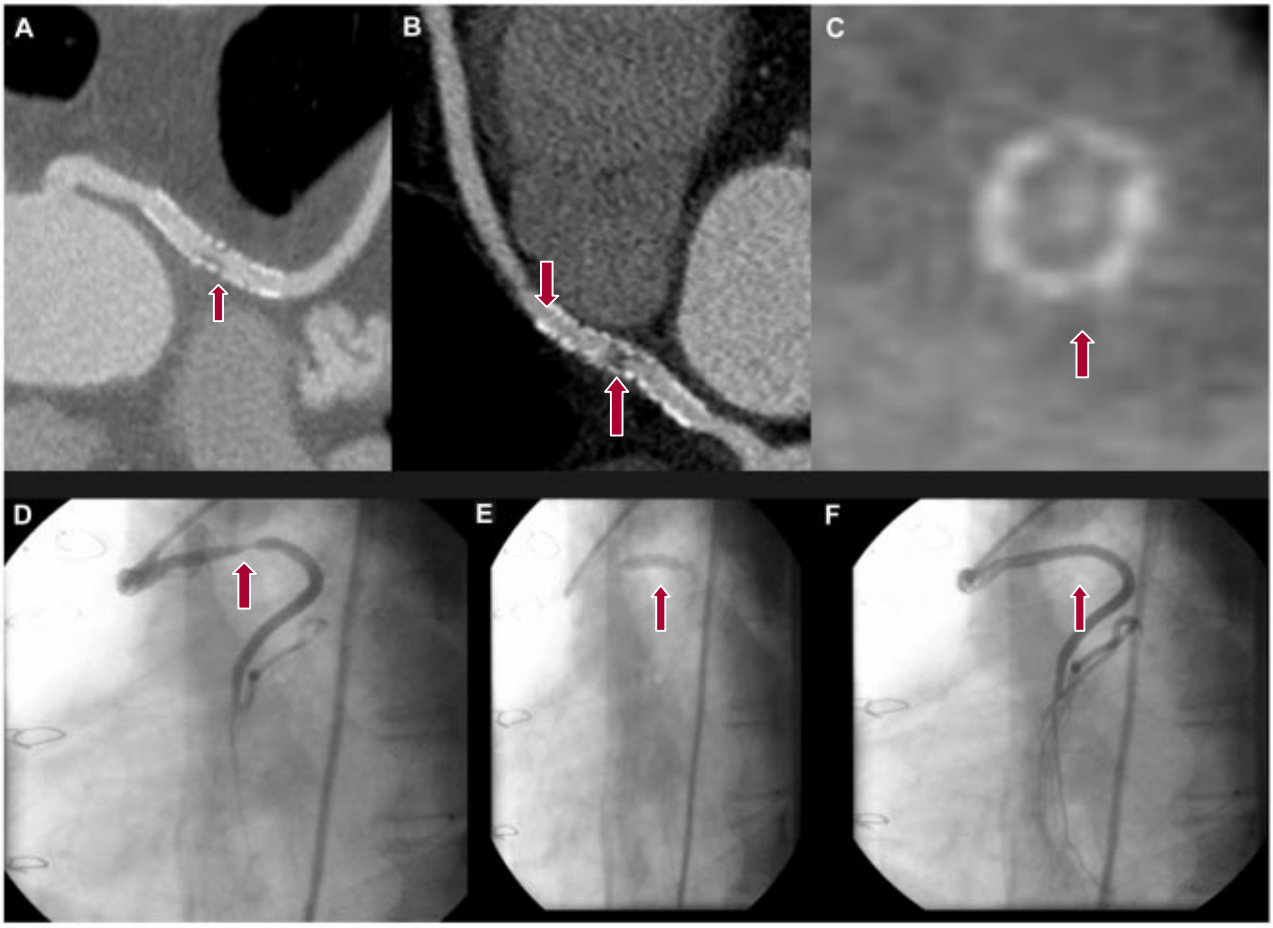

Fig. 1. Invasive (IA) and minimally-invasive (MSCT) angiography. **A.** MSCT. Curved multiplanar reconstruction. Coronary artery bypass graft with focal in-stent restenosis (arrow) in its middle portion. **B.** MSCT. Curved multiplanar reconstruction. Coronary artery bypass graft with in-stent focal restenosis (arrow) in its middle portion. **C.** MSCT. Multiplanar reconstruction. In-stent restenosis: cross-section (arrows). **D.** IA. Focal in-stent restenosis in coronary artery bypass graft (arrow). **E.** IA. Balloon dilation of restenosis (arrow). **F.** IA. Post-interventional final outcome. Without residual restenosis and with TIMI 3 flow.

Department of MSCT of the Instituto de Cardiología y Cirugía Cardiovascular City of La Habana, Cuba
e-mail: vladimiromr@yahoo.es
[1] First Degree Specialist in Cardiology
[2] Consultant Professor in Diagnostic Imaging