CASE REPORT

Pulmonary Embolism of Polymethyl Methacrylate

YANINA CASTILLO COSTA[MTSAC], MAURO GARCÍA AURELIO, HÉCTOR GÓMEZ SANTA MARÍA, CARLOS BARRERO[MTSAC], VÍCTOR MAURO[MTSAC], CARLOS BARRERO[MTSAC]

Received: 10/27/2008
Accepted: 12/03/2008

Address for reprints:
Clínica Santa Isabel
Unidad Coronaria
Directorio 2037 - 6º Piso
Buenos Aires, Argentina
e-mail: yanu_c@hotmail.com

SUMMARY

The first records of pulmonary embolism by polymethyl methacrylate have been recently published (2003) with no more than 15 cases reported. The current case report describes a young patient who underwent percutaneous vertebroplasty with polymethyl methacrylate two months before consultation. The patient complaint of symptoms suggestive of pleural compromise; the chest X-ray showed multiple radio opacities in both pulmonary fields. Pulmonary embolism by polymethyl methacrylate is an infrequent complication related to the procedure; however, it should be ruled out in patients with a history of vertebroplasty who present chest pain or dyspnea.

Rev Argent Cardiol 2009;77:129-130.

Key words > Pulmonary Embolism - Polymethyl Methacrylate

CASE REPORT

A 32-year old male patient visited the emergency room with a one-week history of pleuritic pain in his right chest. He had undergone percutaneous vertebroplasty due to a giant hemangioma of the fifth lumbar vertebra two months before consultation. Physical examination and blood pressure were normal and he did not need oxygen therapy. The electrocardiogram was also normal. The chest X-ray showed multiple radio opacities in both pulmonary fields (Figure 1). A chest computed tomography confirmed the diagnosis of pulmonary embolism (Figure 2). The patient started anticoagulation therapy with low-molecular-weight heparin followed by oral acenocumarol. Doppler echocardiography was normal. The patient presented favorable outcomes and was discharged 72 hours later with a diagnosis of pulmonary embolism by polymethyl methacrylate.

DISCUSSION

Percutaneous vertebroplasty with polymethyl methacrylate was performed by Galibert et al. in 1984 to treat a giant hemangioma of a cervical vertebra. (1) Since that first procedure, this technique has also been used to relieve pain and to increase stability of vertebral bodies in patients with fractures due to osteoporosis or vertebral metastasis. This minimally invasive procedure consists of a percutaneous injection of polymethyl methacrylate in the vertebral body guided by fluoroscopy or computed tomography.

Local complications, such as infections or asymptomatic cement leakage to epidural or venous system and allergies, have been reported. (2) Asymptomatic cement leakage has been described in 30% to 70% of cases according to different series and to the indication of the procedure; it is more frequently associated with the treatment of vertebral metastasis than with osteoporosic fractures. In some cases it may produce compression of the nerves which may require surgery. Asymptomatic drainage migration into the basivertebral venous plexus has been reported in 5% to 17% of cases. (3) However, pulmonary embolism by polymethyl methacrylate is an infrequent complication, with an incidence of 2% to 6% according to the different series (2-3); however, these data might be underestimated as chest X-rays are not routinely obtained following the procedure. Other rare complications are fat or bone marrow embolism. (4)

The first registries of pulmonary embolism by polymethyl methacrylate have been published recently (2003), with 15 cases reported up to now. The clinical presentation varied from chest X-ray findings of asymptomatic pulmonary opacities (5-6) to major complications including respiratory distress, (3) perforation of right-sided cardiac chambers by cement leakage (7) and even death in three cases. (8, 9) The clinical manifestations of pulmonary embolism may occur during the procedure, immediately after, or some days later. (5) Our case is the first report of such a delayed presentation.

The risk of pulmonary embolism by polymethyl methacrylate is greater with the number of vertebral bodies treated, and it seems to be related with three key factors: 1) the viscosity of the cement injected (low viscosity is associated with embolism), 2) the position of the needle in relation to the basivertebral venous plexus, and, 3) overfilling of the vertebral body which might facilitate the migration of the cement to the venous system. (8)

[MTSAC] Full Member of the Argentine Society of Cardiology

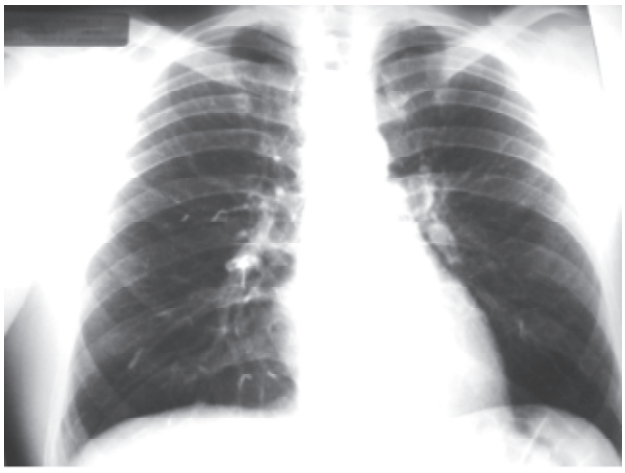

Fig. 1. Anteroposterior chest X-ray. Radio opacities in both pulmonary fields are visualized.

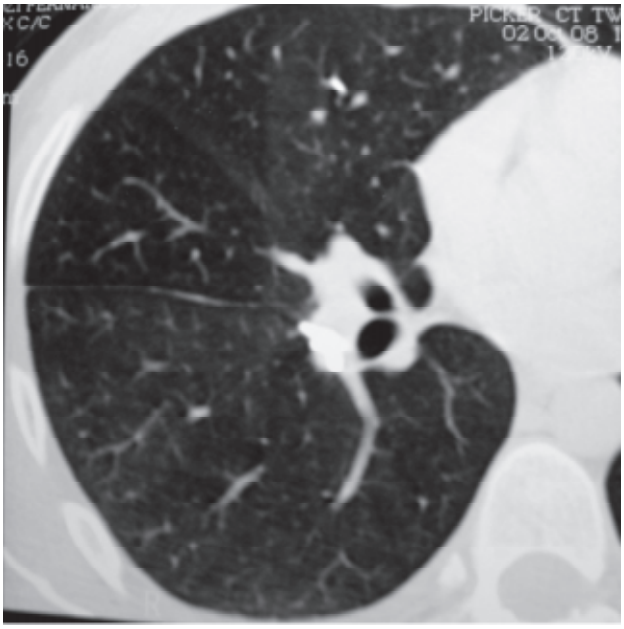

Fig. 2. Chest CT image showing pulmonary embolism of polymethyl methacrylate.

Although these emboli do not originate in a clot, patients should start anticoagulation therapy in absence of contraindications, in order to avoid additional thrombosis of the material. The optimal duration of anticoagulation therapy is unknown. Embolectomy through direct access of the pulmonary arteries and right-sided chambers has been reported in cases of pulmonary embolism and right ventricular dysfunction. (7) There is no evidence of benefit with thrombolytic therapy in these patients.

CONCLUSION

Pulmonary embolism of polymethyl methacrylate should be ruled out in patients with a history of vertebroplasty who present chest pain or dyspnea.

RESUMEN

Embolia pulmonar por polimetilmetacrilato

Los primeros registros de embolia pulmonar por polimetilmetacrilato se publicaron recientemente (2003) y desde entonces se describieron no más de 15 casos. Se presenta el caso de un paciente joven a quien dos meses antes de la consulta se le había efectuado una vertebroplastia percutánea con polimetilmetacrilato. Por síntomas pleuríticos se le realizó una radiografía de tórax, que evidenció múltiples imágenes radioopacas en ambos campos pulmonares. La embolia pulmonar por polimetilmetacrilato es una complicación muy poco frecuente de ese procedimiento y un diagnóstico diferencial para tener en cuenta en pacientes con el antecedente y que consulten por dolor precordial o disnea.

Palabras clave > Embolia pulmonar - Polimetilmetacrilato

BIBLIOGRAPHY

1. Galibert P, Deramond H, Rosat P, Le Gars D. Preliminary note on the treatment of vertebral angioma by percutaneous acrylic vertebroplasty. Neurochirurgie 1987;33:166-8.

2. Moreland DB, Landi MK, Grand W. Vertebroplasty: techniques to avoid complications. Spine J 2001;1:66-71.

3. Zaccheo MV, Rowane JE, Costello EM. Acute respiratory failure associated with polymethyl methacrylate pulmonary emboli after percutaneous vertebroplasty. Am J Emerg Med 2008;26:636.e5-7.

4. Syed MI, Jan S, Patel NA, Shaikh A, Marsh RA, Stewart RV. Fatal fat embolism after vertebroplasty: identification of the high-risk patient. Am J Neuroradiol 2006;27:343-5.

5. Abdul-Jalil Y, Bartels J, Alberti O, Becker R. Delayed presentation of pulmonary polymethylmethacrylate emboli after percutaneous vertebroplasty. Spine 2007;32:E589-93.

6. Bernhard J, Heini PF, Villiger PM. Asymptomatic diffuse pulmonary embolism caused by acrylic cement: an unusual complication of percutaneous vertebroplasty. Ann Rheum Dis 2003;62:85-6.

7. Lim SH, Kim H, Kim HK, Baek MJ. Multiple cardiac perforations and pulmonary embolism caused by cement leakage after percutaneous vertebroplasty. Eur J Cardiothorac Surg 2008;33:510-2.

8. Tozzi P, Abdelmoumene Y, Corno AF, Gersbach PA, Hoogewoud HM, von Segesser LK. Management of pulmonary embolism during acrylic vertebroplasty. Ann Thorac Surg 2002;74:1706-8.

9. Monticelli F, Meyer HJ, Tutsch-Bauer E. Fatal pulmonary cement embolism following percutaneous vertebroplasty (PVP). Forensic Sci Int 2005;149:35-8.