

Mycotic Abdominal Aortic Aneurysm due to *Streptococcus pneumoniae*

MARIANO NORESE¹, MÓNICA DAVARO², SERGIO FERREYRA FERNÁNDEZ¹

Received: 04/24/2012

Accepted: 05/02/2012

Address for reprints:

Address for reprints:

Dr. Mariano Norese
Billinghurst 2072
(C1425DTP) Ciudad Autónoma de
Buenos Aires
E-mail: marianonorese@hotmail.
com

ABSTRACT

Mycotic or infectious aortic aneurysm is rare and presents high morbidity and mortality rates caused by recurrent infection, fulminant sepsis or aortic rupture. We report a case of mycotic abdominal aortic aneurysm due to *Streptococcus pneumoniae* in a female patient with multiple immunosuppressive risk factors, who was successfully treated with surgery and prolonged systemic antibiotic therapy.

REV ARGENT CARDIOL 2013;81:63-64. <http://dx.doi.org/10.7775/rac.v80.i6.1512>

Key words

> Aortic aneurysm - Infected aneurysm - Surgery

CASE REPORT

We report the case of a 58-year-old female patient, smoker and alcohol addict, with type 2 diabetes, under corticosteroid therapy due to herniated lumbar disc, who was admitted to the emergency room with a 48-hour history of abdominal pain in the left flank and iliac fossa, associated with fever (38.5 °C), and leukocytosis (22,500 gb/mm³). Subsequent blood cultures were positive for *Streptococcus pneumoniae* sensitive to penicillin. Physical examination revealed a palpable, pulsatile abdominal mass, and presence of distal pulses. Abdominal CT scan showed a 7 cm saccular dilation of the infrarenal abdominal aorta, associated with preaortic collection of 18 x 50 mm and alterations in the surrounding fat with normal iliac arteries (Figure 1A). These findings were not evident in previous CT scans, which showed normal aortic diameter ten months earlier (Figure 1B). The transesophageal echocardiography revealed healthy heart valves and a free pericardium with preserved systolic function.

The cardiovascular surgery team evaluated the case and decided on surgical treatment. Surgery revealed a purulent collection blocked by jejunal loops, in close contact with the abdominal aortic aneurysm whose anterior wall was eroded allowing mural thrombus visualization (Figure 2). Drainage of collection, debridement of infected tissue, and infrarenal aortic replacement with a 20-mm Dracon patch were performed. Microscopic pathology showed leukocyte infil-

tration throughout the width of the aneurysmal aortic wall. The patient progressed favorably and 3 months later continued on outpatient antibiotic treatment.

DISCUSSION

Mycotic or infectious aortic aneurysm is rare and presents high morbidity and mortality rates due to recurrent infection, fulminant sepsis or aortic rupture. (1-2) Its prevalence is between 0.7 and 2.6% depending on the studied series. (3, 4) At present, it occurs mainly as a result of vascular trauma or intravenous drug abuse, and is often present in patients with some degree of immunosuppression. (2, 5) The most common microorganism found in blood, aneurysmal wall and periaortic tissue cultures is *Salmonella*, followed by *Escherichia coli* and *Staphylococcus aureus*, while infection caused by *Streptococcus pneumoniae* is rare. (1, 5, 6) Clinical manifestations are fever and abdominal pain, which are generally accompanied by positive blood cultures and leukocytosis, while the occurrence of collections or periaortic soft tissue inflammation on the CT scan reinforce the diagnosis of mycotic aneurysm. Surgery is the treatment of choice, always associated with prolonged antibiotic therapy. It allows drainage of collections and debridement of infected tissue, followed by extra-anatomic bypass or in-situ prosthetic graft replacement which has better long-term patency outcome. (1, 4, 5) The endovascular repair in these cases has only been reported for small

¹ Cardiovascular Surgery Team - Clínica Bazterrica. Buenos Aires, Argentina

² Infectious Diseases Specialist- Clínica Bazterrica

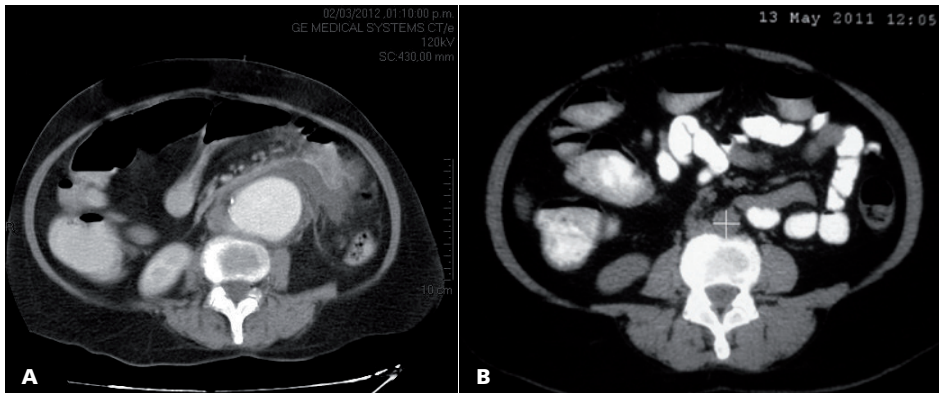


Fig. 1. A. CT image of the infrarenal aortic aneurysm associated with perianeurysmal collection at the moment of introduction. **B.** CT scan of the same patient, ten months earlier, in which no aneurysmal formation is observed.

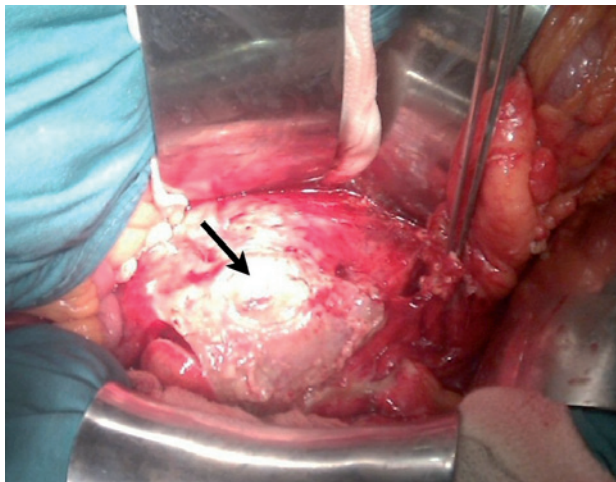


Fig. 2. Surgical image of mycotic aneurysm with erosion of the anterior abdominal aortic wall.

series with short-term follow-up. Moreover, its role is very controversial, since it does not remove the infection from the aortic wall. (2, 7)

RESUMEN

Aneurisma micótico de la aorta abdominal por *Streptococcus pneumoniae*

El aneurisma micótico o infeccioso de la aorta es infrecuente y, dadas la recurrencia de la infección, la sepsis fulminante o la rotura aórtica, posee una morbimortalidad elevada. En

esta presentación se describe un caso de aneurisma micótico de la aorta abdominal por *Streptococcus pneumoniae* en una paciente con múltiples factores de riesgo de inmunodepresión, que fue tratada exitosamente en forma quirúrgica y con antibioticoterapia sistémica prolongada.

Palabras clave > Aneurisma de aorta -
Aneurisma infectado - Cirugía

Conflicts of interest:
None declared.

REFERENCES

1. Lai H, Luo CY, Lin PY, Kan CD, Chang RS, Wu HL, et al. Surgical consideration of in situ prosthetic replacement for primary infected abdominal aortic aneurysms. *Eur J Vasc Endovasc Surg* 2011;42:617-24. <http://doi.org/dwvjfd>
2. Zhou T, Guo D, Chen B, Jiang J, Fu W, Wang Y. Endovascular stent-graft repair of mycotic aneurysms of the aorta: A case series with a 22-month follow-up. *World J Surg* 2009;33:1772-8. <http://doi.org/ds4j3d>
3. Oderich GS, Panneton JM, Bower TC, Cherry KJ Jr, Rowland CM, Noel A, et al. Infected aortic aneurysm: aggressive presentation, complicated early outcome, but durable results. *J Vasc Surg* 2001;34:900-8. <http://doi.org/cfkf7>
4. Fichelle JM, Tabet G, Cormier P, Farkes JC, Laurian C, Gigou F, et al. Infected infrarenal aortic aneurysms: when is in situ reconstruction safe? *J Vasc Surg* 1993;17:635-45. <http://doi.org/csr9rp>
5. Hsu RB, Chen RJ, Wang SS, Chu SH. Infected aortic aneurysms: Clinical outcome and risk factor analysis. *J Vasc Surg* 2004;40:30-5. <http://doi.org/b6v5s7>
6. Coutu M, Blair JF. Multiple mycotic aortic aneurysms due to *Streptococcus pneumoniae*. *Ann Vasc Surg* 2003;17:554-7. <http://doi.org/b2pcbw>
7. Ishizaka N, Sohmiya K, Miyamura M, Umeda T, Tsuji M, Katsumata T, et al. Infected aortic aneurysm and inflammatory aortic aneurysm - In search of an optimal differential diagnosis. *J Cardiol* 2012;59:123-31. <http://doi.org/fx42fd>