

## Anomalous Origin of Coronary Arteries from a Common Arterial Trunk in the Right Sinus of Valsalva

### To the Editor

The anomalous origin of coronary arteries is a rare abnormality that has been associated to myocardial ischemia and occasional sudden death. (SD). There are different presentations, among which, the origin of the left main coronary artery in the right sinus of Valsalva is a very uncommon one.

A 50-year old woman with no history of cardiovascular risk factors was admitted to the hospital due to sudden chest pain. The electrocardiogram revealed 1 mm ST segment depression in the anterior and lateral walls. She was admitted to the Coronary Care Unit with diagnosis of unstable angina. Troponin I was 1.85 (cut-off value: 0.04). Her outcome was satisfactory, without symptom recurrence. The coronariography (Figure 1) revealed absence of significant stenoses and origin of right coronary (RC), left main anterior descending (AD) and circumflex (CX) arteries from a common trunk in the right coronary sinus. The patient progressed well and was discharged. A 64-slice computed tomography coronary angiography confirmed the diagnosis (Figure 2), revealing AD artery inter-aorto-pulmonary trajectory, with an intramyocardial segment at the level of the interventricular septum, absence of coronary lesions and high calcium score of 18.

Subsequent perfusion studies did not show ischemia.

The prevalence of anomalous origin of coronary arteries is about 1% in angiographic studies, a percentage which is even lower in necropsy records. At first, these anomalies were considered simple findings. However, their diagnosis became relevant from stud-

ies showing the importance of their detection, specially the evaluation of their initial trajectory and the relationship with aortic and pulmonary arteries (PA) because of the probable compression they might exert on the coronary arteries. (2) There are plenty of possible presentations, from a completely silent and benign one to forms that evolve with syncope, angina, infarction and/or arrhythmias. Severe symptoms have been communicated in around 20% of cases. Sudden death has been mainly associated with physical exertion, particularly relevant in documented SD in athletes. The as yet undetermined precise mechanism responsible for these symptoms has given rise to different hypotheses: arterial constriction during physical exertion in anomalies involving inter-arterial trajectory between the aorta and the PA, intramural trajectory in the aortic wall mainly at the origin of the artery and origin of coronary arteries with excessive angulation may result in compressive phenomena leading to ischemic conditions. (3) Different presentations have been described, spanning the coronary ostium in the contralateral sinus or in the non-coronary sinus, presence of a single coronary artery, origin from another coronary artery and the anomalous origin from the pulmonary artery.

Classically, two great groups of anomalies are described: origin and distribution anomalies and coronary fistulae, the former being the most frequent ones in a 4:1 ratio. The anomalous origin of the left coronary artery in the right sinus of Valsalva occurs very rarely in nearly 0.15% of cases. (4)

Surgical indication is controversial and it is not

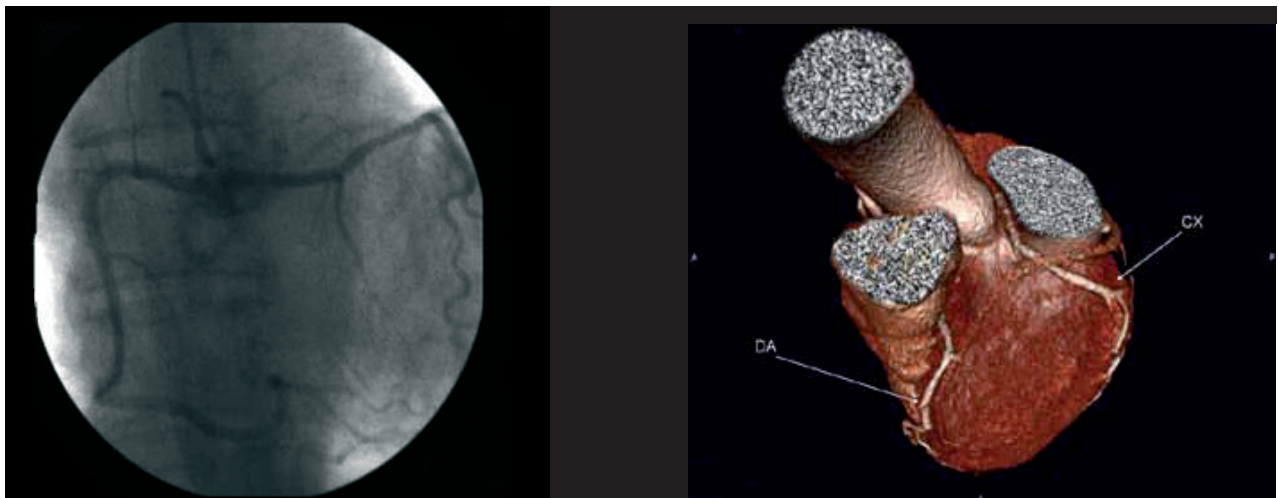


Fig. 1.

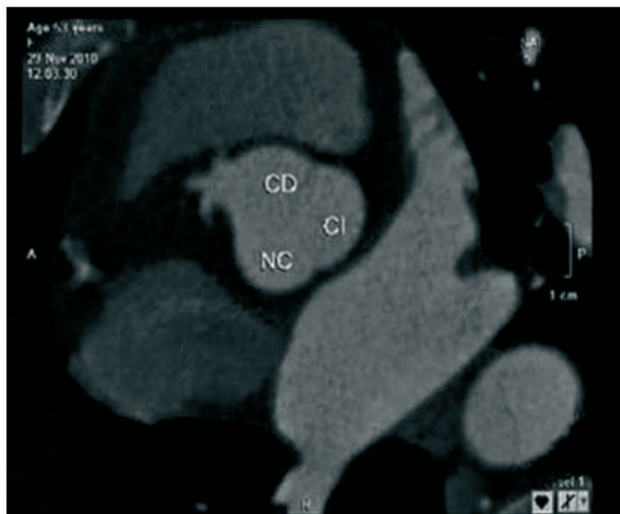


Fig. 2.

very clear in asymptomatic patients with no evidence of ischemia. Stress-rest SPECT has shown to be useful to identify at risk patients and select candidates for surgical correction. (5)

**Dr. Federico Rocca, Leonardo Onetto L.,  
Cynthia Scarano, Geraldine Cura,  
Juan P. Barrio, Germán Ramallo**  
Hospital Interzonal General de Agudos "Dr. José Penna"  
Lainez 2401 - (8000) Bahía Blanca  
Pcia. de Buenos Aires, Argentina

#### REFERENCES

1. Angelini P, Velasco JA, Flamm S. Coronary anomalies: incidence, pathophysiology, and clinical relevance. *Circulation* 2002;105:2449-54. <http://doi.org/bh8phc>
2. Taylor AJ, Byers JP, Cheitlin MD, et al. Anomalous right or left coronary artery from the contralateral coronary sinus: "high risk" abnormalities in the initial coronary artery course and heterogeneous clinical outcomes. *Am Heart J* 1997;133:428-35. <http://doi.org/dt7gmp>
3. Ugalde H, Ramírez A, Ugalde D, et al. Nacimiento anómalo de las arterias coronarias en 10000 pacientes sometidos a coronariografía. *Rev Med Chile* 2010;138:7-14. <http://doi.org/fkmmhj>
4. Angelini P, Villason S, Chan AV. Normal and anomalous coronary arteries in humans. En: Angelini P, editor. *Coronary artery anomalies: a comprehensive approach*. Philadelphia: Lippincott Williams and Wilkins; 1999. p. 27-150.
5. De Luca L, Bovenzi F, Rubini D, et al. Stress-rest myocardial perfusion SPECT for functional assessment of coronary arteries with anomalous origin or course. *J Nucl Med* 2004;45:532-6.

*Rev Argent Cardiol* 2013;81:256-257 - <http://dx.doi.org/10.7775/rac.v81.i3.968>

#### Aortopulmonary Fistula

##### To the Editor

Aortopulmonary fistula is rare entity. (1) It is a malformative communication between the aorta and the pulmonary artery, which can be congenital or acquired,

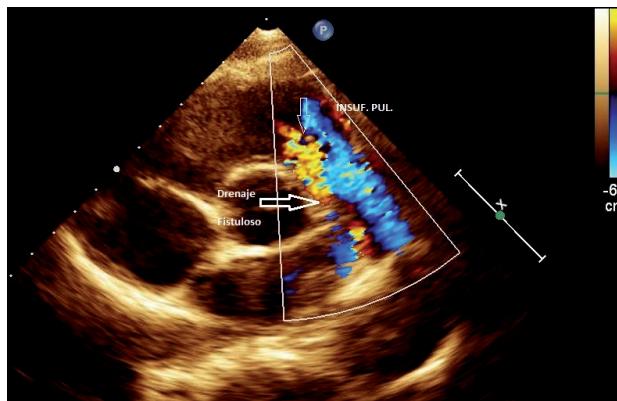


Fig. 1.

and occurs mostly as the result of sinus of Valsalva aneurysms. Its complication arises from left to right volume overload due to pulmonary hyperflow and heart failure, and is corrected with surgical treatment. (2) In most cases, the diagnosis is made by aortography or echodoppler, (3, 4) but also by transesophageal echo or X-ray computed tomography.

A 36-year old male patient, with history of apparent good health, was referred to our clinic due to moderate to high exertion-induced dyspnea. He was in functional class II (NYHA), with broad peripheral artery pulses, suprasternal pulse, apex beat at the left fifth intercostal space midclavicular line, and thrills. On auscultation he presented a normal first heart sound, fixed-split second pulmonary sound and continuous pulmonary murmur.

Echocardiographic parasternal short-axis view at the level of the great vessels revealed main pulmonary artery (PA) dilation, turbulent flow from the aorta to the main PA and jet of pulmonary regurgitation (Figure 1).

Due to the need of surgical treatment, a computed tomography was performed that confirmed the diagnosis of aortopulmonary fistula (Figure 2)

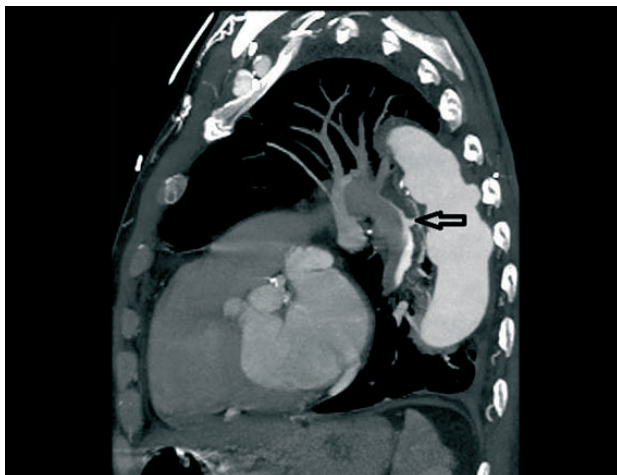


Fig. 2.

The patient underwent uneventful surgery. Other centers close the fistula using an Amplatzer device. (3, 5)

**Dr. Eudis Reyes Mozo, Yordalis Segura Durán,  
Antonio Felizola Rodríguez**

Hospital Universitario "Celestino Hernández Robau"  
Calle 6ta No. 236 B, e/ F y G,  
Vigia. Santa Clara, Villa Clara. Cuba  
e-mail: eudisreyes1976@yahoo.es

#### REFERENCES

1. Sakashita I, Yokosawa T, Suzuki C. Aorticopulmonary fistula. A case of successful repair with review of literature since 1943. *Jpn Heart J* 1976;17:676-84.

2. Heikkinen LO, Järvinen AA. Aortopulmonary fistula after coarctation repair with Dacron patch aortoplasty. *Ann Thorac Surg* 2002;73:1634-6.

3. Lachurie M, Mercier L, Castonguay Y. Aortopulmonary fistula detected by echocardiography 12 years after aortoplasty for correction of ascending aorta aneurysm. *J Am Soc Echocardiogr* 1992;5:456-8.

4. Feigenbaum H, Amstrong W, Ryan T. *Ecocardiografía*. Madrid: Editorial Médica Panamericana; 2007. p. 678-81.

5. Piciche M, De Paulis R, Fabbri A. Postoperative aortic fistulas into the airways: etiology, pathogenesis, presentation, diagnosis, and management. *Ann Thorac Surg* 2003;75:1998-2006.

---

*Rev Argent Cardiol* 2013;81:257-258 - <http://dx.doi.org/10.7775/rac.v81.i3.1630>