

Acute Myocardial Infarction and Cocaine: Three Pathophysiological Models

In recent years, growing cocaine use worldwide has increased the rate of associated cardiovascular complications.

Some studies found that about 30% of the addiction visits to emergency services are associated with cocaine use. (1) Cocaine use causes acute and chronic pathological manifestations in several organs, the cardiovascular system being one of the most affected. Regarding acute coronary syndromes (ACS), different pathophysiological models associated with cocaine use have been described. (1, 2) We present three cases of patients with ACS who evidenced different pathophysiological substrates.

Pathophysiological model 1: coronary dissection (3)

A 25-year-old male patient, with extensive anterior acute myocardial infarction (AMI), was referred from another center for coronary angiography (CAG) and possible angioplasty. He reported cocaine use from age 14 to the present time. After 48 hours of cocaine use, he had oppressive chest pain radiating to his left arm. On admission, the patient was hemodynamically stable, asymptomatic for angina and similar disorders. The ECG showed poor R-wave progression from leads V1 to V4, with ST segment elevation and negative T-wave. Enzymatic curve: Peak CPK 1111 U/L and CPK-MB 98 U/L (on admission). The echocardiography confirmed hypokinesia in all the apical segments with apical thrombus. The coronary angiography showed the left main coronary artery (LMCA), the circumflex artery (CX) and the right coronary artery (RCA) without angiographically significant lesions, and the anterior descending artery (ADA) with proximal spontaneous dissection with superimposed thrombus, and TIMI III flow (Figure 1A). Due to the clinical condition of the patient and the CAG results, pharmacological treatment (ASA, clopidogrel, nitrates, enalapril and heparin anticoagulation) with reevaluation of the lesion in seven days were decided. During that time, there were no complications, and a new CAG showed complete resolution of the dissection (Figure 1B).

The patient was discharged with antiplatelet therapy, carvedilol, enalapril and anticoagulation with acenocoumarol (apical thrombus). The patient is currently under follow-up by the ACS outpatient clinic and for his addiction (he had a relapse after the event).

Pathophysiological model 2: atherosclerosis

This is the case of a 45-year-old male patient, who referred oppressive chest pain of 20 minute duration. He reported a previous AMI, with angioplasty in the ADA in 2007 and cocaine use from age 16. He

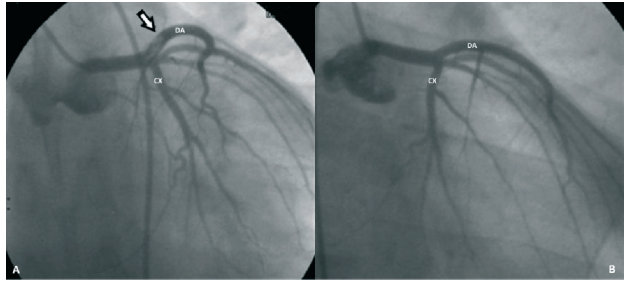


Fig. 1. A. Descending coronary artery showing absence of filling with irregular contrast retention at the proximal segment, corresponding to spontaneous dissection with superimposed thrombus (arrow); preserved distal flow. The circumflex artery did not show angiographically significant lesions. **B.** After 7 days of drug therapy, the follow-up angiography showed complete resolution of the dissection and superimposed thrombus (arrow). ADA: Anterior descending artery. CX: Circumflex artery.

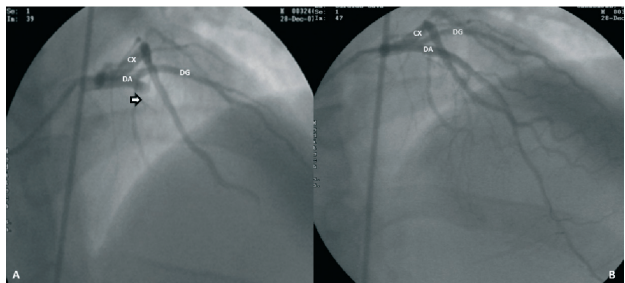


Fig. 1. A. Anterior descending coronary artery, showing plaque with a superimposed thrombus at the level of the proximal segment (arrow); TIMI 0 flow. The circumflex artery did not show angiographically significant lesions. **B.** Follow-up angiography after angioplasty with bare metal stent. ADA: Anterior descending artery. CX: Circumflex artery. DG: Diagonal branch

was an athlete, with no other common cardiovascular risk factors. On admission, the patient was hemodynamically stable, asymptomatic for angina. The ECG showed ST segment elevation from V1 to V4. The CAG revealed a unique lesion in the proximal ADA with superimposed thrombus and TIMI 0 flow (Figure 2A). Due to the patient's clinical status and the CAG result, the patient underwent angioplasty with stent placement in the LAD coronary artery (Figure 2B). During hospitalization, the patient remained asymptomatic without complications. Treatment at hospital discharge was ASA, clopidogrel, atorvastatin, enalapril, and carvedilol.

The patient is currently under follow-up by the ACS outpatient clinic, but he is under no drug rehabilitation therapy (he abandoned treatment 2 months ago and is currently taking drugs).

Pathophysiological model 3: vasospasm

A 38-year-old female patient, with extensive anterior acute myocardial infarction, was referred from

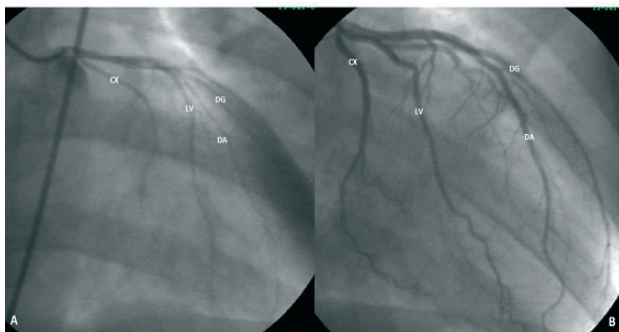


Fig. 3. A. Anterior descending coronary artery with severe vasospasm and distal TIMI I flow. The circumflex artery also shows vasospasm without angiographically significant lesions. B. Follow-up angiography after intracoronary nitroglycerin injection. ADA: Anterior descending artery. CX: Circumflex artery; LV: Lateral ventricular branch of circumflex artery. DG: Diagonal branch.

another center for coronary angiography (CAG) and possible angioplasty. She had a history of tobacco smoking, and marijuana and cocaine use. On the day of the episode, the patient referred cocaine use, and then had oppressive chest pain radiating to her neck, with 8/10 intensity. On admission, the patient was hemodynamically stable, symptomatic for angina. The ECG showed 4 mm ST segment elevation from V1 to V5. The severity of angina and ST segment elevation decreased after intravenous nitroglycerin infusion. In spite of this, and since the patient remained with angina 4/10 and 2 mm ST segment elevation in anterior wall precordial leads, a CAG was performed, showing diffuse vasospasm in LMCA and CXA, and severe vasospasm in ADA which improved with intracoronary nitroglycerin (Figure 3A & B). Due to the patient's clinical status and the result of the CAG, pharmacological therapy was decided (nitrates and calcium blockers). The enzymatic curve showed peak CPK of 860 U/L.

The patient was discharged and is currently under follow-up by the ACS outpatient clinic, and drug rehabilitation therapy (without relapse).

DISCUSSION

Use of cocaine should be investigated in patients with ACS, especially in young ones, since it would influence on their pathophysiological interpretation, therapy management and follow-up. Ischemic complications associated with the use of cocaine are based on various pathophysiological mechanisms. These mechanisms include vasospasm, coronary dissection, atherosclerosis-plaque rupture, and increased myocardial oxygen demand. (1, 2) Among the different types of ACS, AMI has an incidence of approximately 6%. (1)

This drug behaves like an indirect sympathomimetic amine, increasing catecholamine availability in the synaptic gap (inhibiting the reuptake process). The pathophysiology by which cocaine produces myocar-

dial ischemia consists of increased catecholamine levels and their effect mediated by alpha-adrenergic and beta-adrenergic stimulation.

The vasospastic effect (case 3) is caused by coronary vasoconstriction, mainly by alpha-adrenergic action (exacerbated by beta-adrenergic blockade). Other factors include increased endothelin I in plasma and reduced nitric oxide production (mediator of the local vasodilator effect). (4, 5)

Another pathophysiological phenomenon described is coronary dissection (case 1). The processes that would encourage its development include increased levels of catecholamines resulting in high blood pressure, tachycardia and elevated cardiac inotropic state, which enhance wall stress at the level of the coronary endothelium. (6, 7) That sequence of events is responsible for intimal flap formation and subsequent dissection, occlusion of true lumen and progression of the acute coronary event. Non-traumatic dissections associated with cocaine use are extremely rare and scarcely documented in worldwide literature. (3, 6, 7) However, they are of common occurrence in ACS patients with ST segment elevation.

Cocaine use also speeds up the development of atherosclerosis in young adults with no conventional risk factors, with the risk of future recurrent ischemic events (as shown in our case 2). (5-8) The endothelial dysfunction mentioned above would be responsible for this process. Some studies have revealed that chronic cocaine consumption is associated with endothelial cell damage, altering several cell functions which cause cell deterioration and release of injury markers. (9)

Secondary factors of ischemia in cocaine users include hypertension and tachycardia.

Regarding treatment management, sublingual or intravenous nitrates are indicated to counteract the vasospastic effect of cocaine on the arteries. Calcium blockers have a similar effect. (1) Antiplatelet and antithrombotic agents play an important role in the management of patients with AMI associated with cocaine use. (1) The use of beta-blockers in cocaine-using patients with ACS is controversial, because it would increase vasospasm through alpha stimulation effect. (4, 5) No data on beta-blockers and AMI associated with cocaine were found.

In case of persistence of the clinical condition in ACS patients with ST segment elevation, the main therapy is reperfusion.

The evaluation of other cardiovascular risk factors and treatment are also suggested. It is vital for these patients' prognosis to enter a rehabilitation program for their addiction. An example in the cases reported here are those who were unable to rehabilitate and had readmissions for ACS. Follow-up after the event should be multidisciplinary (cardiologist, psychologist, and psychiatrist).

In conclusion, ischemia induced by cocaine is associated with different pathophysiological mechanisms,

either isolated or combined. The use of cocaine should be investigated in patients with ACS, especially in young ones with no typical risk factors, since it would influence on their pathophysiological interpretation, therapy management and follow-up.

Gabriel Pérez Baztarrica MD, Flavio Salvaggio MD, Sandra Zamar MD, Rafael Porcile MD ^{MTSAC}

Department of Cardiology. Chair of Physiology. University Hospital - Universidad Abierta Interamericana. School of Medicine
Dr. Gabriel Pérez Baztarrica
Portela 2975 - (1437). CABA, Argentina
Phone (054)1149187561
e-mail: gpbaztarrica@yahoo.com

REFERENCES

1. Schwartz B, Rezkalla S, Kloner R. Cardiovascular effects of cocaine. *Circulation* 2010;122:2558-69. <http://doi.org/d3s2jz>
2. Benzaquen B, Cohen V, Eisenberg M. Effects of cocaine on the coronary arteries. *Am Heart J* 2001;142:402-10. <http://doi.org/ftwfgd>
3. Pérez Baztarrica G, Gariglio L, Salvaggio F, Arellano J, Marchetti G, Botbol A y cols. Diseción de arterias coronarias asociada con el consumo de cocaína. *Rev Argent Cardiol* 2008;76:399-402.
4. Pozner C, Levine M, Zane R. The cardiovascular effects of cocaine. *J Emerg Med* 2005;29:173-8. <http://doi.org/dfs5dt>
5. Afonso L, Mohammad T, Thatai D. Crack whips the heart: a review of the cardiovascular toxicity of cocaine. *Am J Cardiol* 2007;100:1040-3. <http://doi.org/cw754m>
6. Steinhauer J, Caulfield J. Spontaneous coronary artery dissection associated with cocaine use: a case report and brief review. *Cardiovasc Pathol* 2001;10:141-5. <http://doi.org/dmd57p>
7. Eskander K, Brass N, Gelfand E. Cocaine abuse and coronary artery dissection. *Ann Thorac Surg* 2001;71:340-1. <http://doi.org/bs8d97>
8. Patrizi R, Pasceri V, Sciahbasi A, Summaria F, Rosano GM, Lioy E. Evidence of cocaine-related coronary atherosclerosis in young patients with myocardial infarction. *J Am Coll Cardiol* 2006;47:2120-2. <http://doi.org/dts2j8>
9. Sáez CG, Olivares P, Pallavicini J, Panes O, Moreno N, Massardo T, et al. Increased number of circulating endothelial cells and plasma markers of endothelial damage in chronic cocaine users. *Thromb Res* 2011;128:e18-e23. <http://doi.org/fgwxpp>

Rev Argent Cardiol 2013;81:510-512 - <http://dx.doi.org/10.7775/rac.v81.i6.1816>

Acute Myocardial Infarction with Multivessel Thrombosis after Freebase Cocaine Use

We report the case of a 39-year-old male patient, heavy smoker, who presented with chest pain associated with ECG evidence of posterolateral, inferior, subepicardial lesion involving the right ventricle (Figure 1). He referred having used cocaine until two hours before the event. Blood pressure was 80/40 mm Hg and heart rate was 98 beats per minute. Physical examination showed jugular ingurgitation with clear lungs. Acute myocardial infarction (AMI) was assumed to be in progress, and an aspirin/prasugrel loading dose was administered. The patient was transferred for primary angioplasty (PTCA), which showed proximal occlusion of the right coronary artery with thrombus, requiring thromboaspiration. A bare metal stent was

implanted, and final TIMI 3 flow was achieved after infusion of intracoronary nitroglycerin. Left cardiac catheterization showed angiographic amputation of the circumflex artery, with persistence of precordialgia without resolution of ST segment elevation on the lateral wall. This outcome required new thromboaspiration and bare metal stent implantation, with good final flow (Figure 2). The echocardiography revealed severe left ventricular function impairment, with inferior akinesis and hypokinesis in the rest of the segments (Figure 3).

During evolution, the patient had onset of diabetes with ketoacidosis, digestive hemorrhage due to erosive gastritis, and shock due to right ventricular clinical involvement with associated left ventricular failure requiring inotropic support. Peak creatine phosphokinase was 16259 mg/dl with MB fraction of 896 mg/dl, which caused renal failure reversed with transient dialysis. The patient made good progress and is currently under follow-up.

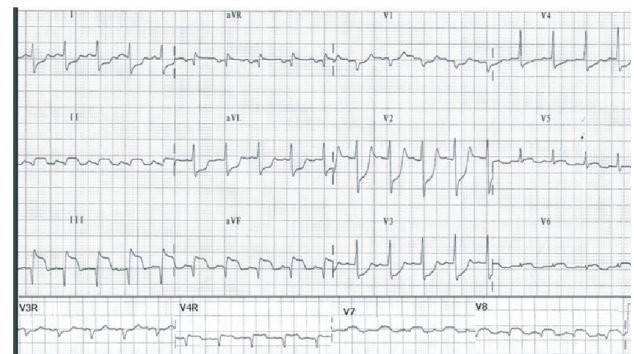


Fig. 1. Electrocardiogram at the time of admission shows an inferior, posterior, low lateral subepicardial lesion, and signs of RV infarction.

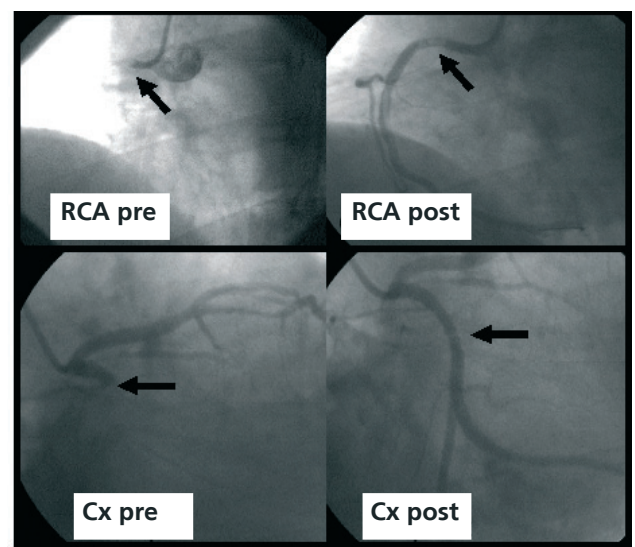


Fig. 2. Coronary angiography showing occlusion of the right coronary artery and circumflex coronary artery (pre-RCA and pre-CX) with thrombus image (arrows). Good residual flow is observed after angioplasty (post-RCA and post CX).

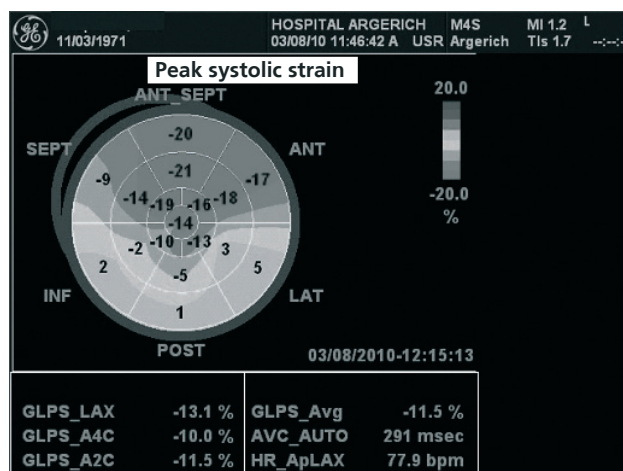


Fig. 3. Strain echocardiography showing disorders in inferoposterolateral deformation, matching the area of myocardial lesion in the ECG

DISCUSSION

According to the 2008 National Survey on the Prevalence of Psychoactive Substance Use conducted in Argentina, (1) 2% of the total population of the country is estimated to use cocaine with a higher proportion of men and high incidence in the Greater Buenos Aires. Although chest pain is the most common cardiac manifestation, only 5.7% of patients with cocaine-associated ischemic symptoms have myocardial infarction, probably because various mechanisms have been implied in the cardiovascular toxicity and pathophysiology of chest pain. (2)

Cardiovascular diseases are the main manifestations arising from cocaine intoxication. The mechanisms involved in their pathogenesis include presynaptic norepinephrine-dopamine reuptake inhibition and blockade of sodium channels which promote re-entry arrhythmias, and the direct alpha-adrenergic effect produced by vasospasm. In addition to these effects, generation of acute phase reactants stimulates activation and platelet aggregation promoting thrombus formation, a mechanism that could have had an important role in this patient. (3)

Regarding angiographic findings, it is relatively common to find two occluded arteries in the context of a myocardial infarction, one responsible for the acute event and the other one responsible for a previous event. Angiographically, intimal dissection, filling defects or thrombus image suggest acute thrombotic occlusion, and it is crucial to identify the culprit vessel. Multiple complicated plaques have been reported in patients during the course of a myocardial infarction; nevertheless, the present case is one of the few with simultaneous total occlusion of two arteries. This phenomenon is uncommon in clinical practice; however, necroscopic studies in patients who died from AMI showed an incidence of 10% to 50%, mainly in those with hemodynamic deterioration. (4) It is pos-

sible that the actual incidence of this phenomenon is greater than that reported in the literature, since many of these cases are reported as out-of-hospital sudden deaths.

There are reports from patients with AMI and acute multiple coronary thrombosis that account for the case presented here. A review article by Kanei et al. (5) proved that most patients were males, smokers, of an age-range divided into two peaks: old patients (with predominant comorbidities such as cancer or essential thrombocytosis) or young adults (with a history of HIV or cocaine use). About 50% of the patients had occlusion of the right coronary artery or the circumflex artery, with a lesion of the inferior wall, as in the case presented here. Aspiration thrombectomy was used in only some of them, while the majority of patients required stent implantation for both lesions. Pollak et al. (6) also reported their experience with patients presenting with AMI and angiographically documented acute thrombosis. They found an incidence of about 2.5% of AMI patients requiring PTCA, with significant underdiagnosis because of the need for image testing to determine simultaneous thrombosis and because they presented with out-of-hospital sudden death before they were diagnosed. Smoking was particularly noted as the main risk factor, and the severity of this condition was demonstrated with the high prevalence of mechanical and electrical complications. This author gave name to an unknown entity, which had been reported since the 1980s in isolated cases as a mere coincidence of thrombotic events. Both authors attribute this phenomenon mainly to activation of cytokines, proinflammatory and procoagulant substances, which, by extending to the coronary vasculature during AMI, causes rupture-prone plaques, aggravating the condition. This hypothesis is confirmed by the presence of inflammatory infiltration in both AMI culprit and non-culprit plaques, as evidenced in anatomopathological studies. (7) In addition to this mechanism, contributing factors include hypercoagulability, primary vasospasm or secondary vasospasm to exposed subendothelium after plaque accident and prolonged hypotension with coronary flow reduction, promoting formation of new thrombi. Presumably, cocaine use in this patient with increased atherosclerotic load could have caused multiple plaque activation resulting in simultaneous acute thrombosis. Although acute multiple thrombosis is a heterogeneous condition in which panvascular inflammation involvement explains most of the cases, unraveling the intimal mechanisms of this condition will help us find unexplained answers in heart disease.

**Alberto Cozzarín MD, Juan Gagliardi MD^{MTSAC},
Miguel Riccitelli MD^{MTSAC}**

Hospital General de Agudos "Dr. Cosme Argerich"
Dr. Alberto Cozzarín
Pi y Margal 780 - 2° Piso. División Cardiología.
(1155) CABA, Argentina
e-mail: acozzarin@intramed.net
Tel. 11 4302-5538 / 11 63502781

REFERENCES

1. INDEC: Estudio Nacional sobre Consumo de Sustancias Psicoactivas 2004 (ENCoSP-2004) y Encuesta Nacional sobre Prevalencias de Consumo de Sustancias Psicoactivas 2008 (ENPreCoSP-2008). Disponible en: <http://www.indec.mecon.ar/>
2. Hollander JE, Hoffman RS, Gennis P, Fairweather P, Disano MJ, Schumb DA. Prospective multicenter evaluation of cocaine-associated chest pain. COCHPA Study Group. *Acad Emerg Med* 1994;1:330-9. <http://doi.org/dsjgh7>
3. Afonso L, Mohammad T, Thatai D. Crack whips the heart: A review of the cardiovascular toxicity of cocaine. *Am J Cardiol* 2007;100:1040-3. <http://doi.org/cw754m>
4. Burke A, Virmani R. Significance of multiple coronary artery thrombi. A consequence of diffuse atherosclerotic disease? *Ital Heart J* 2000;1:832-4.
5. Kanei Y, Janardhanan R, Fox JT, Gowda RM. Multivessel coronary artery thrombosis. *J Inv Cardiol* 2009;21:66-8.
6. Pollak PM, Parikh SV, Kizilgul M, Keeley EC. Multiple culprit arteries in patients with ST segment elevation myocardial infarction referred for primary percutaneous coronary intervention. *Am J Cardiol* 2009;104:619-23. <http://doi.org/dh5wcn>
7. Sarmiento RA, Blanco F, Parisi C, Fandiño S, Gigena G, Blanco R. Actividad inflamatoria en múltiples placas ateroscleróticas en pacientes fallecidos por infarto agudo de miocardio. *Rev Argent Cardiol* 2009;77:81-7.

Rev Argent Cardiol 2013;81:512-514 - <http://dx.doi.org/10.7775/rac.v81.i6.2024>