

ments are poorly correlated with thermodilution measurements, and underestimate them. In addition, we have found that concordance limits between the two methods are broad, therefore, they are not interchangeable.

Previously, other authors, such as Ishiara or Yamada, had found different results. However, in those cases, the initial calibration of the esCCO system had been performed based on the cardiac output provided by thermodilution, and not by the automatic exclusion algorithm with the data from the patient's hemodynamic trend.

Thereafter, a new algorithm was developed to perform the calibration of the equipment based on patient data. The most attractive feature of this non-invasive method is precisely that it does not require the patient's instrumentation, but if the data provided by the calibration algorithm are not comparable to those of the Swan Ganz, the method would lose all its benefit.

Recently, Takashi found an error of -0.4 ± 1.1 l/min in kidney-transplant patients, even though the calibration of the device had been performed with the calibration algorithm along with patient data, and not based on the data provided by PAC.

Conversely, other authors have concluded that, while non-invasive features of this new technology and the ability for continuous cardiac output measurement make it attractive when using current algorithms, the error level is too high and questions the usefulness of the method for decision-making.

Critchley and Critchley had previously stipulated that, for a minimally invasive method to be acceptable, it should have an error $<30\%$; however, that limit is too wide, as adding the intrinsic error of the Swan Ganz would increase it by 45%.

It is also interesting to highlight the possible influence of systemic vascular resistance on esCCO measurements as previously pointed out by other authors; however, this is not fully understood, and its true role is unknown.

Another factor to be considered is the use of vasopressors in our population. The use of noradrenaline has been described as one of the elements interfering with the plethysmographic variability index; in our work, correlation improved significantly in patients without noradrenaline compared with those receiving vasopressors (R^2 0.3 vs. 0.02) (Figure 2).

The small number of patients was the main limitation of our work. On the other hand, most patients were undergoing postoperative liver transplantation. In these patients, changes in systemic the hemodynamics and vascular resistances of the different territories after surgery could impact on cardiac output.

Despite these limitations, we can confirm that in this population the esCCO system was not able to assess cardiac output values.

Conflicts of interest

None declared.

(See authors' conflicts of interest forms on the website/ Supplementary material).

**Maria Cecilia González, Ariel Dogliotti,
Araldo Dubin, Carlos Lovesio**
E-mail:ceciliagonzalez83@yahoo.com.ar

Rev Argent Cardiol 2019;87:231-232. <http://dx.doi.org/10.7775/rac.v87.i3.13360>

REFERENCES

1. Sugo Y, Ukawa T. A novel continuous cardiac output monitor based on pulse wave transit time. *Conf Proc IEEE Eng Med Biol Soc* 2010;10:2853-6. <http://doi.org/bv64r8>
2. Ishihara H, Okawa H. New non-invasive continuous cardiac output trend solely utilizing routine cardiovascular monitors. *J Clin Monit* 2004;18:313-20. <http://doi.org/fvx9mf>
3. Ishihara H, Sugo Y, Tsutsui M, Yamada T, Sato T, Akazawa T, et al. The ability of a new continuous cardiac output monitor to measure trends in cardiac output following implementation of a patient information calibration and an automated exclusion algorithm. *J Clin Monit Comput* 2012;26:46571. <http://doi.org/f4dvc6>
4. Biais M, Cottenceau V, Petit L, Masson F, Cochard JF, Sztark F. Impact of norepinephrine on the relationship between pleth variability index and pulse pressure variations in ICU adult patients. *Crit Care* 2011;15:R168. <http://doi.org/fkqhw3>

Polymorphic Ventricular Tachycardia and Long QT Syndrome Associated with Clarithromycin Therapy

We report the case of a 73 year-old female patient, allergic to penicillin, ex-smoker, with a history of hypertension (HT), chronic obstructive pulmonary disease (COPD), anticoagulated paroxysmal atrial fibrillation (AF), and a VVIR permanent pacemaker (PMK) implantation in the last year due to cardiogenic syncope in the context of brady-tachycardia syndrome.

The patient was admitted to hospital due to hypertensive acute pulmonary edema (APE), with adequate response to diuretic therapy and intravenous (IV) vasodilator. Moreover, the patient presented with a clinical condition consistent with exacerbated COPD, for which treatment with IV clarithromycin was started at a dose of 500 mg every 12 hours. The ECG on admittance revealed: sinus rhythm, heart rate (HR) 75 bpm, QRS axis between -30° and -60° , P wave 80 ms, PR interval 160 ms, QRS 160 ms, QTc 391 ms and complete left bundle branch block image.

Seventy two hours after admission, the patient developed multiple episodes of nonsustained polymorphic ventricular tachycardia (nsVT) with hemodynamic decompensation, manifested with presyncope (Figure 1). Surface ECG revealed PMK rhythm alternating with own sinus rhythm, complete left bundle branch block image at HR of 75 bpm, polymorphic ventricular extrasystoles (VE) with R-on-T phenomenon, fusion and pseudofusion beats, and prolonged QT interval with QTc of 671 ms (Figure 2).

It was decided to stop clarithromycin therapy; ten hours later the QT interval was normalized and the

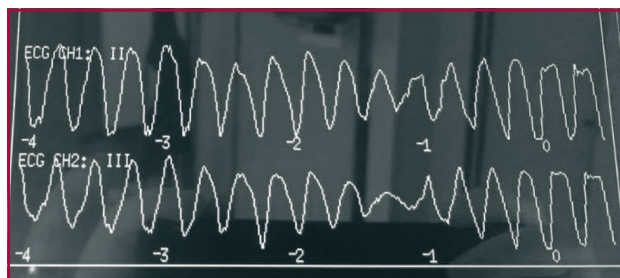


Fig. 1. Monitoring of nonsustained polymorphic ventricular tachycardia.

episodes of nsVT disappeared, and none of them were recurrent during hospitalization. At discharge, she presented ECG in atrial fibrillation rhythm, HR 130 bpm, QRS 140 ms, QRS axis between -30° and -60° , and QT 360 ms.

Polymorphic ventricular tachycardia can occur with long QT interval either for congenital or acquired reasons. It is commonly induced by antiarrhythmic drugs that prolong ventricular repolarization.

Various pharmacological agents can cause marked prolongation of the QT interval. These include antibiotics - particularly macrolides - such as clarithromycin, which blocks IKr, prolonging QT interval through its active metabolite (14 (R)-hydroxy-clarithromycin). (1)

This drug is frequently used as treatment for respiratory tract infections; however, little is known about its association with the risk of sudden death and cardiovascular death, (2) as evidenced by the few cases reported so far.

However, observational studies report an increase in sudden death and cardiovascular death associated with macrolides, especially in patients with high baseline cardiovascular risk. (3)

Heart diseases, as well as female sex and old age, may promote arrhythmias. (4)

Several common polymorphisms in almost all the genes associated with long QT syndrome have been described, such as K897T (HERG), which is present in up to 15% of the population and is not only linked with susceptibility to certain drugs, but also favors the pathogenic effect of mutations in the same gene. (5)

A population-based study that used a national registry of more than 3,300,000 subjects included in the period 1997-2011, identified a total of 160,297 patients treated with clarithromycin. The total number of cardiac deaths in this group was 18. Clarithromycin was associated with a significantly increased risk of cardiac death during antibiotic administration (RR 2.07, 95% CI 1.28 to 3.35). (6) The absolute risk for clarithromycin use was 37 cardiac deaths per 1 million of patients treated (95% CI 4 to 90).

In our patient, the clear temporal relationship between QTc prolongation and induction of arrhythmia within 72 hours of treatment onset, the development

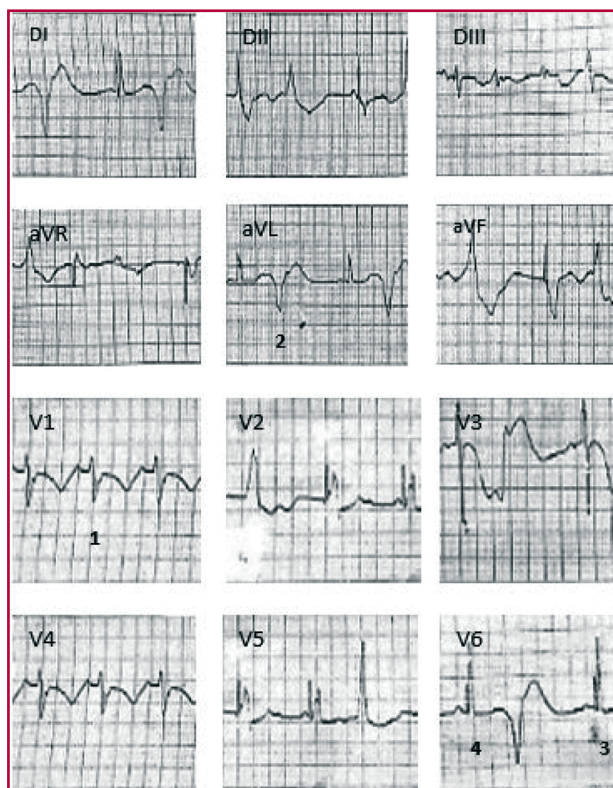


Fig. 2. ECG showing PMK rhythm alternating with own sinus rhythm, (1) complete left bundle branch block image at heart rate of 75 bpm, polymorphic ventricular extrasystoles with R-on-T phenomenon, (2) fusion (3) and pseudofusion (4) beats, and prolonged QT interval (QTc 671 ms).

of ventricular tachycardia, and the progressive normalization of the ECG after clarithromycin discontinuation, suggest that this drug was a triggering factor.

In conclusion, although there are no sufficient data to modify the prescription of this drug, the presence of risk factors should be taken into account when indicating clarithromycin therapy.

Conflicts of interest

None declared.

(See authors' conflicts of interest forms on the website/ Supplementary material).

**Sofía Di Mattia, Sebastián Garraza,
Yanina Simón, Pablo Brussa**
Sanatorio Mayo, Santa Fe, Argentina
E-mail: sofidimatt@hotmail.com

Rev Argent Cardiol 2019;87:232-233. <http://dx.doi.org/10.7775/rac.v87.i3.14609>

REFERENCES

- Lanzotti M, Citta N. Síndrome de QT Largo Adquirido "Torsade de Pointes". Fed Argent Cardiol 2003;2-3. <http://www.fac.org.ar/tevc/llave/c312/lazotti.htm>.
- Chang NL, Shan P, Bikkina M, Shamoof F. Clarithromycin-induced Torsade de Pointes. Am J Ther 2016;23:e955-6. <http://doi.org/f8n7tz>.

3. Ray WA, Murray KT, Hall K, Arbogast PG, Stein CM. Azithromycin and the risk of cardiovascular death. *N Engl J Med* 2012;366:1881-90. <http://doi.org/f3xwvj>.
4. Vieweg WV, Hancox JC, Hasnain M, Koneru JN, Gysel M, Baranchuk A. Clarithromycin, QTc interval prolongation and torsades de pointes: the need to study case reports. *The Adv Infect Dis* 2013;1:121-38. <http://doi.org/c4dd>.
5. Medeiros-Domingo A, Iturralde-Torres P, Ackerman MJ. Clínica y genética en el síndrome de QT largo. *Rev Esp Cardiol* 2007;60:739-52. <http://doi.org/drhrnz>.
6. Svanstrom H, Pasternak B, Hviid A. Use of clarithromycin and roxithromycin and risk of cardiac death: cohort study. *Br Med J* 2014;394:g4930. <http://doi.org/gb3snm>.

Atrial Myxoma as a Cause of Acute Myocardial Infarction

Primary cardiac tumors are extremely uncommon and often asymptomatic with an incidence ranging from 0.0017% to 0.28%; (1) atrial myxomas are the most frequent benign primary cardiac tumors, and are mainly localized in the left atrium. They predominantly occur in women with an average age of onset in the 6th decade of life. (1, 2) According to their morphologic characteristics, two types of myxomas are described: type 1 myxomas are smooth and rounded, and of compact consistency; while type 2 myxomas are papillary and of fragile consistency, prone to embolization. Around 30% of the patients with myxoma present with signs and symptoms associated with secondary embolization in the territory of any peripheral artery; actually, it is the overlying thrombus on the surface of the tumor that presents greater embolization rather than the tumor itself, although this phenomenon may occur in type 2 myxomas. The risk for embolization increases with tumors <4.5 cm, especially affecting the central nervous system and retinal arteries. (2) Coronary embolism is rare, but isolated cases of ischemic heart disease secondary to this phenomenon have been reported in the presence of myxoma.

We describe the case of a 24-year-old female patient with left atrial myxoma who presented inferior wall ST-segment elevation acute myocardial infarction.

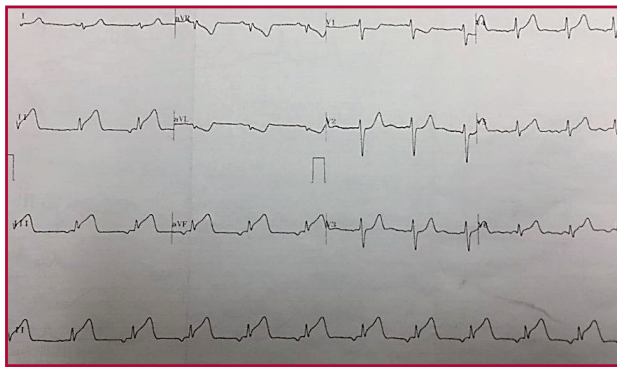


Fig. 1. ECG taken three hours after the onset of chest pain, showing low atrial rhythm and subepicardial lesion current in the inferior wall.

The patient had no history of cardiovascular diseases, and exhibited typical angina-like chest pain following moderate physical exertion. An ECG performed in another hospital revealed subepicardial lesion in the inferior wall, causing her transfer to our hospital 14 hours after the onset of pain.

On admission, the patient was asymptomatic, hemodynamically stable, with ECG signs of inferior necrosis and increased troponin levels. A diagnosis of evolving inferior ST-segment myocardial infarction was made and a coronary angiography showed normal coronary arteries. An echocardiogram reported a left atrial myxoma in the interatrial septum, protruding into the left ventricular chamber.

Laboratory results of lipid profile, collagen disease markers, and thrombophilia were negative. The patient was referred to cardiac surgery for myxoma resection. Resection of a 6 cm x 3.5 cm myxomatous tumor attached to the inferior left atrial wall and the interatrial septum was performed. The histopathological study confirmed the diagnosis of atrial myxoma with irregular surface.

Coronary embolization as complication of atrial myxoma is extremely rare; its incidence is only 0.06%, (3) due to the right angled junction of the coronary openings in the aortic root, the protection of the coronary arteries by the aortic valve cusps and the small diameter of the coronary sinuses. (4) There is no association with age or gender. In 48.8% of patients with coronary syndrome secondary to embolism due to myxoma, normal coronary arteries have been reported, especially in young patients. This finding has been associated with spontaneous recanalization, although its mechanism is still unclear. (4, 5) The inferior wall has been affected in 43.2% of the cases reported. (5) Transthoracic echocardiography is the study of choice for the diagnosis of atrial myxoma. In this case, the patient is young, without cardiovascular risk factors, with evidence of inferior wall ST-segment myocardial infarction and normal coronary arteries, and after ruling out prothrombotic disorders, we believe her condition was secondary to embolization of the atrial myxoma.

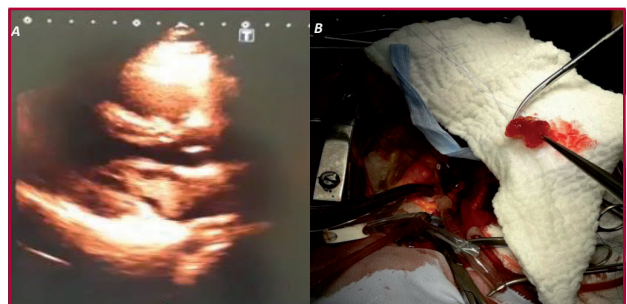


Fig. 2. A. Transthoracic echocardiography showing intra-atrial mass suggestive of myxoma. **B.** Image of surgically removed myxoma.