

Diagnosis of Tuberculosis in Pediatric Patients. Current State of Knowledge

Diagnóstico de tuberculosis en pacientes pediátricos. Estado actual del conocimiento

Luque, Graciela F.³; Melillo, Karina C.³; Lombardero, Lorena A.³; González, Norma E.⁴; Bisero, Elsa D.³

Diagnostic study group for TB

González, Claudio D.¹; Símboli, Norberto F.²; Bisero, Elsa D.³; Luque, Graciela F.³; Melillo, Karina C.³; Lombardero, Lorena A.³; González, Norma E.⁴; Amiano, Nicolás O.⁵; García, Verónica E.⁵; Duré, Roberto M.⁶; Armitano, Rita I.⁷; Fruhwald, Gladys E.⁸; Cerqueiro, María C.⁹

Received: 10/11/2022

Accepted: 11/01/2023

Correspondence

Claudio D. González. E-mail: claudiogonzalez57@gmail.com

DIAGNOSIS OF TB IN PEDIATRIC PATIENTS

1. Approach to the diagnosis of childhood tuberculosis (CTB)

Dr. Elsa Bisero

The incidence of childhood tuberculosis (CTB) is often underestimated due to the difficulty of diagnosing the disease in children. The clinical presentation of TB in pediatric patients shows significant variability, with sometimes oligosymptomatic forms that occur in a latent manner. Pediatricians must make an effort to understand this disease and prevent its progression to severe forms, thus contributing to its epidemiological control.

In 2020, the WHO (World Health Organization) estimated that globally, each year, 1,100,000 children under 15 years old fall ill with TB, and among them, 226,000 lose their lives. This represents approximately 11 % of the total number of TB cases. 80 % of these deaths occur in children under 5 years of age, and 17 % in patients infected with HIV (human immunodeficiency virus). It is estimated that between 25,000 and 32,000 children under 15 years old develop multidrug-resistant tuberculosis (MDR-TB) each year. Only 12,220 of them started treatment between 2018 and 2020.^{1, 2}

In Argentina, during 2020, 10,896 cases of tuberculosis were reported, of which 10,268 were new cases and relapses. 17 % of the cases correspond to children and adolescents. 76.9 % of the newly diagnosed cases were pulmonary.³

Rev Am Med Resp 2023;23:257-269
<https://doi.org/10.56538/ramr.WNWy6973>

¹ Pulmonology and Tisiology Unit, Hospital General de Agudos José M. Ramos Mejía, City of Buenos Aires. Argentina.

² Mycobacteria Service, Instituto Nacional de Enfermedades Infecciosas Dr. Carlos G. Malbrán, INEI-ANLIS. City of Buenos Aires, Argentina.

³ Pediatric Service. Pediatric Pulmonology Section, Hospital Nacional Prof. Dr. Alejandro Posadas. El Palomar, Province of Buenos Aires. Argentina.

⁴ Pulmonology and Tisiology Unit, Hospital General de Niños Pedro de Elizalde. City of Buenos Aires. Argentina.

⁵ Researchers from CONICET (National Scientific and Technical Research Council) Immunology and Tuberculosis Laboratory of the Institute of Biological Chemistry, Faculty of Exact Sciences and natural Sciences (IQUBICEN), University of Buenos Aires (UBA), City of Buenos Aires. Argentina.

⁶ Bronchoscopy Unit, Hospital de Infecciosas Francisco J. Muñiz. City of Buenos Aires. Argentina.

⁷ Mycobacteria Laboratory. Hospital General de Agudos Parmenio Piñero. City of Buenos Aires. Argentina.

⁸ Pulmonology Service of the Obra Social del Personal de Edificios de Renta y Horizontal (OSPERYH).

⁹ Consultant of the Tisiology Section. Hospital de Niños Dr. Ricardo Gutiérrez. City of Buenos Aires. Argentina.

Childhood tuberculosis (CTB) can be diagnosed relatively simply and, in the vast majority of cases, it can be cured with low-cost, well-tolerated treatments. Nevertheless, it continues to pose a challenge for public health.⁴

The **purpose** of this chapter is to provide appropriate guidelines for the diagnostic methodology, describe its characteristics (sensitivity and specificity performance), and formulate recommendations for its use.

The **goal** is to establish a set of recommendations for detecting suspected cases of CTB based on the best available scientific evidence and expert consensus.

The **mission** of this section is aimed at detecting children with TB, and the **vision** is constructed in terms of patients' needs, system requirements, and the individuals' quality of life.

The **overall objective** of this chapter is to provide updated tools for the diagnosis of CTB.

2. The role of the anamnesis in the diagnosis of CTB

Dr. Karina Melillo

The anamnesis is fundamental and should be thorough and systematic. The first step in the diagnosis is to suspect the possibility of TB. In any outpatient or hospital consultation, it is imperative to gather personal and environmental information regarding manifestations of chronic disease compatible with TB. When taking a detailed anamnesis, important epidemiological aspects should be considered both for the patient and also from the perspective of public health. This assessment encompasses various aspects.

As **personal history**, considerations include BCG vaccination, the presence of a post-vaccination scar, and a prior tuberculin test (TT), including its date of administration and result. If the individual received previous anti-tuberculosis treatment or chemoprophylaxis, it is necessary to determine the date, drugs used, duration, any intolerance, instances of discontinuation, and interruptions. Additionally, it's important to identify comorbidities, immunodeficiencies, and potential immunosuppressive treatment.

Regarding the patient's **family history**, it is important to inquire about any focus studies, the history of current TB cases or those within the last two years in the patient's environment, clini-

cal symptoms, and therapeutic measures taken. It is crucial to specify the duration of exposure, whether it is a bacillary or cavitory case, the drug resistance status, to record treatment adherence, and ensure a comprehensive study of contacts. Furthermore, maintaining open communication with the professionals overseeing the index case is essential.

If the child is the index case, meaning that no known TB patient emerges during the anamnesis, it is essential to search for the bacillary focus among contacts with respiratory symptoms (RS), as it could be a patient who has not yet been diagnosed.⁵⁻⁷

In children, TB is considered a sentinel event, indicating recent community transmission from a bacillary adult.^{7,8}

All children at risk of having TB should be studied and classified as exposed, infected, or sick. Each stage requires a different therapeutic approach, and certain factors, such as a history of present illness, should be carefully evaluated.⁸

The age at which the infection occurs and the immune status are the two most important variables determining progression to disease. Babies and toddlers, especially those under 2 years old, have a high probability of developing active disease, with the majority experiencing it within a year of the primo-infection.⁹ Additionally, these young children have a greater risk of developing severe and disseminated forms of the disease, which are often fatal. The risk is lower for those between 5 and 10 years old and increases again during adolescence. It's important to note that most immunocompetent children infected with *M. tuberculosis* will not become sick, but immunodeficient individuals should always be studied in areas where TB is prevalent.⁸

The systematic detection of TB disease in children is a challenge. Diagnostic tools are less accurate in children than in adults. Children have lower yield from microbiological tests. Bacteriological confirmation in the pediatric population is achieved in less than 40 % of the cases. Since the reference method (gold standard) for the diagnosis is still the direct detection of *M. tuberculosis* in biological samples or its cultivation in specific media, the delay in awaiting results can lead to late diagnosis and treatment.

3. The role of clinical symptoms in the diagnosis of CTB

The **clinical presentation** of TB is highly variable and can be less expressive (in the majority of cases), leading to diagnostic delays, disease progression, and new infections.

The onset is often insidious and chronic. Symptoms vary with age, TB type (primary or post-primary), the extent of the disease, and the patient's immune status.

The most common presentation of TB in children is the gangliopulmonary form, and most of these patients will exhibit few symptoms or be asymptomatic.⁸

Signs and symptoms result from the compression of the airway and parenchyma by enlarged lymph nodes; this is more common in infants and young children due to the smaller caliber of the airways. They often present with a dry cough (persistent for more than two weeks), mild dyspnea, and fixed, persistent, asymmetric wheezing that does not respond to bronchodilator treatment, whether with or without tachypnea. In children under 3 years old, symptoms may mimic viral infections, and this creates diagnostic challenges. Weight loss or poor weight gain, along with fever (with or without night sweats), occur with the progression of the disease, reaching 89 % sensitivity and 69 % specificity for detecting CTB.⁴ In children under 3 years old, sensitivity drops to 50 %. In this age group, it is important to screen for lethargy and decreased activity (decreased play), as cough may be absent.^{10, 11} A recent Cochrane review concludes that the combination of one or more symptoms would have a sensitivity of 89 % in detecting pulmonary TB in children who are in close contact with TB cases.¹¹ The diagnosis of TB should also be ruled out in children with severe pneumonia that does not improve with the appropriate antimicrobial treatment, or with pleural

effusion (more common in children under 2 years old and immunosuppressed), raising the level of suspicion (see Table 1).^{2, 7, 8, 12-14}

Towards the end of childhood and during adolescence (≥ 10 years of age), primary forms as those described, or post-primary forms of reinfection (endogenous or exogenous) may occur, similar to those found in adults. It is more likely that these patients will experience classic symptoms of bacillary impregnation, such as evening fever, anorexia, malaise, weight loss (documented in the last 3-6 months, or a loss greater than 10 % of body weight in any time interval, unresponsive to nutritional treatment), night sweats, persistent cough lasting more than two weeks, either dry or productive with purulent or hemoptoic mucous expectoration, pleuritic chest pain, and hemoptysis. Physical examination findings are usually milder than in younger children or may even be absent. Most of them present with normal respiratory auscultation, even when there are cavities or large infiltrates.^{10, 13}

In **extrapulmonary forms of TB**, the signs and symptoms corresponding to the affected organ, apparatus, or system predominate.¹⁰

- Non-painful adenopathy, especially larger than 2×2 cm, with or without fistula. **Nodal TB.**
- Spinal kyphosis with narrow angle (angular swelling), especially if it is of recent onset (gibbus). **Spinal TB.**
- Signs of non-acute meningitis (lasting for more than 5 days), especially if unresponsive to antibiotic treatment or with elevated intracranial pressure. **Meningeal TB.**
- Pleural effusion, especially unilateral dullness with pleuritic pain in a child who is not acutely ill. **Pleural TB.**
- Pericardial effusion, distant or muffled heart sounds, or signs of new-onset heart failure. **Pericardial TB.**

TABLE 1. Typical and atypical CTB symptoms (modified from the Operational Handbook on Tuberculosis)

Typical CTB symptoms	Atypical CTB symptoms
Persistent cough	Localized wheezing (mostly in children under 5 years old) with no response to treatment).
Prolonged fever with or without night sweats	Severe pneumonia (more common in children under 2 years old and immunosuppressed).
Decreased appetite, anorexia	
Weight loss or poor weight gain	
Fatigue, decreased play or activity	

- Non-acute distended abdomen with or without ascites. **Abdominal TB.**
- Non-painful swollen joints with painful or abnormal gait. **Osteoarticular TB.**

It is important to take into account the **erythema nodosum** and **phlyctenular keratoconjunctivitis**, which are manifestations of hypersensitivity to Koch's bacillus proteins and suggest recent tuberculous infection.

With the concept of a **continuous process** between two extremes ranging from infection with *Mycobacterium tuberculosis* (Mtb) to tuberculosis disease, two intermediate stages have recently been incorporated, described as **incipient TB**, which is the stage following the infection previously referred to as latent TB (LTB). Dormant bacilli alternate with periods of slow and intermittent replication. The patient likely does not have the ability to transmit the disease. Methods of diagnosis of infection, such as IGRAs (interferon-gamma release assays) and PPD (purified protein derivative), are positive. There are no validated methods for the diagnosis of this stage. At this stage, the development of biomarkers capable of detecting it and preventing its progression to **subclinical TB** is promising. Subclinical TB is a stage in which metabolically active bacilli are replicating, and it is potentially infectious. It is characterized by the absence of symptoms and clinical signs, or by the presence of symptoms and signs in a mild form without the patient's perception, which favors the spread of the disease within the community. This has very negative implications for children under 5 years old, especially those under 2 years old, in whom there is a higher risk of getting sick and developing severe forms of the disease. The tools for detection are imaging and microbiological tests.¹⁵

In summary: There are no clinical findings that confirm the diagnosis of CTB. However, there are signs that should raise the level of suspicion. An algorithm based solely on symptomatic signs is insufficient. Relying only on symptoms carries a 30 % risk of studying or treating children who are not sick with TB.^{4, 8, 10} The Guidelines recommend supplementing with microbiological and imaging studies, which increases the possibility of obtaining a TB diagnosis.²

4. The function of clinical analyses

Dr. Lorena Lombardero

The findings are usually nonspecific, and the results are only indicative: moderate hypochromic

iron deficiency anemia, erythrocyte sedimentation rate (ESR) ≥ 80 mm³ in the first hour (may exceed 100/mm³ in HIV/AIDS patients), elevated C-reactive protein (≥ 10 mg/L), leukocytosis with neutrophilia, and a left shift in the Schilling index.

As with other acute-phase reactants, C-reactive protein has good sensitivity; in countries with a high prevalence of TB, it is around 90 %, but its specificity is low (53 % to 75 %).¹⁵

The concentration of C-reactive protein is also elevated in pleural effusions due to TB; if it is higher than 50 mg/L, it has a specificity of 95 %. Adenosine deaminase (ADA) is a sensitive and specific biomarker (varying between 88 % and 100 %, and between 81 % and 97 %, respectively) for pleural TB, especially in regions with medium or high disease prevalence. It has similar diagnostic effectiveness in HIV patients, even in those with low levels of CD4 lymphocytes. The ADA2 isoenzyme, predominant in monocytes and macrophages, accounts for 88 % of the total ADA activity in pleural TB. The LDH (lactate dehydrogenase)/ADA ratio can discriminate between tuberculous effusion and parapneumonic effusion, especially with a lower cutoff point.^{16, 17}

Other efficient markers for pleural TB include the cytokine IFN- $\gamma \geq 75$ pg/mL, interleukin 27 (IL-27), or lysozyme >15 mg/dL (lysozyme ratio in fluid/serum greater than 1.2). These markers could be useful in pleural TB, but they are more expensive.¹⁸

5. The role of the tuberculin test in the diagnosis of CTB

Dr. Graciela Luque

It is the most useful method for the diagnosis of tuberculous infection and is of great help for the diagnosis of the disease in both children and adolescents. It is a quantitative method, measuring the delayed hypersensitivity reaction to proteins of the purified protein derivative (PPD) (tuberculin hypersensitivity). It only indicates previous contact of the individual with the bacillus. The technique must be rigorous and shall be performed by trained personnel. The Mantoux technique, with reading 72 hours after injection is recommended. The reaction is measured according to the induration produced, which should be measured in millimeters over the maximum diameter, transversely to the long axis of the forearm. Erythema is not taken into account. Positive induration or the appearance of vesicles or necrosis are indicative of

TB infection. Table 2 shows the cutoff values used in our country for interpreting results.^{3,19}

Epidemiological research has indicated that the host's genetic component contributes to infection and disease phenotypes, influencing both susceptibility and resistance. Approximately 30 %-50 % of exposed cohabiting contacts do not become infected. Several family studies have provided consistent evidence of the significant role of human genetics in the control of *M. tuberculosis* infection or reactivity to PPD.²⁰

Conversion or tuberculin shift

Conversion or tuberculin shift occurs when a tuberculin-negative individual becomes tuberculin-positive, or there is a difference of more than 10 mm between two readings within a period of less than 2 years. This is considered indicative of recent infection.¹⁹ The negativity of the TT in children does not exclude the diagnosis of tuberculous infection or disease. Therefore, it should be noted that it does not constitute a diagnostic element in

itself but rather an additional criterion to consider when evaluating a positive reaction to tuberculin.

Inconveniences of tuberculin Some of the protein elements of PPD (Purified Protein Derivative) are shared by environmental mycobacteria and *M. bovis* (BCG), and this reduces the specificity of the test. The lack of results for being absent at the second reading visit worsened by the inability to repeat the test immediately.²¹

Table 3 summarizes the advantages and disadvantages provided by the TT.

Latest tests in the diagnosis of the infection

The new tests for diagnosing TB infection are based on concepts similar to PPD and IGRA, that is, eliciting an immune response to specific antigens of *M. tuberculosis*, either *in vivo* (skin induration size) or *in vitro* (magnitude of cytokine release). There is still a pending need for a test that not only correctly identifies healthy carriers but also those at a high risk of developing the disease, in order to intervene with treatment.

TABLE 2. Positivity thresholds for the Mantoux reaction in our environment

No induration or induration \leq 4 mm	– Children with a negative test.
With induration \geq 5mm	– Children in close contact with the index case or suspected TB. – Children suspected of clinical or radiological tuberculosis. – Children with immunosuppression or HIV infection. – Children with conversion from a previously negative tuberculin test.
With induration > 10 mm	– Always considered positive.

TABLE 3. TT advantages and limitations

ADVANTAGES
<ul style="list-style-type: none"> – Low cost, accessible to all tuberculosis care programs. – The technique is simple. – High specificity in our environment.
LIMITATIONS
<p>False positives</p> <ul style="list-style-type: none"> – Booster effect. – Booster effect. – Incorrect application, storage, or reading (not a strict false positive but rather a technical error). <p>Falsos negativos</p> <ul style="list-style-type: none"> – Severe tuberculosis disease (tuberculin anergy). – Recent infection (within 6 to 8 weeks of exposure). – Concurrent viral disease (measles, chickenpox, HIV, Epstein Barr disease) or bacterial disease (<i>Bordetella pertussis</i>). – Immunosuppressive treatment, including corticosteroids. – Complement depletion. – Severe malnutrition or dehydration. – Fever. – Recent vaccination (\leq 6 weeks) with live virus vaccines (e.g., chickenpox, measles). – Newborns. – Lymphoproliferative diseases and other immunodeficiencies. – Incorrect application, storage, or reading (not a strict false positive but rather a technical error).

In general, the predictive performance of any new TB infection test should not be inferior to current technology. IGRAs (QFT and T-SPOT) have become routine tests for diagnosing presumed *M. tuberculosis* infection in low-prevalence countries, either alone or in combination with PPD.

IGRAs are more specific and require only one visit for phlebotomy. However, a second visit is often necessary to clarify the result, rule out active TB, and start prevention. IGRAs also have several disadvantages, including the need for complex laboratory infrastructure and sample transportation, higher costs, variability within individuals, and a high proportion of indeterminate results in advanced HIV and very young children. They can yield false positives with non-tuberculous mycobacteriosis, including *M. marinum* and *M. kansasii*.^{21, 22}

Other tests: C-Tb (Statens Serum Institut Copenhagen, Denmark) and **Diaskintest** (CJSC Generium, Russia) are skin reactions based on two specific antigens of *M. tuberculosis*: ESAT-6 and CFP-10. They are applied and read in the same way as the tuberculin test with PPD. They use a 5 mm induration as the cutoff point regardless of the BCG or HIV status. Costs and sensitivity are similar to the Mantoux test. They can be used for population testing and do not cross-react with BCG.^{23, 24}

Conclusion: in the context of diagnostic algorithms for pediatric TB, the tuberculin test and IGRAs are tools that provide specificity and allow the identification of healthy carriers and those at high risk of developing tuberculosis. They should **not** be interpreted in isolation.

6. The role of diagnostic imaging in CTB

6.1 The role of chest X-rays and computed tomography scans

Dr. Norma González

The chest X-ray is a valuable tool for the diagnosis of CTB in pediatrics, as many children show minimal symptoms at the onset of the disease, and pulmonary lesions are often closed with a low quantity of bacilli (paucibacillary), making microbiological confirmation challenging.

When interpreting chest imaging, it is essential to recognize normal structures such as the thymus or pulmonary vessels to avoid misclassifying an X-ray as pathological. In this regard, inappropriate radiological techniques can also be confusing,

leading to mediastinal widening or increased pulmonary segments, in plates taken during expiration, rotated, or poorly penetrated. There is also interobserver variability in the detection and interpretation of images, particularly in cases of primary pulmonary TB in young children.²⁵

Paratracheal, intrathoracic, and perihilar adenomegalies are characteristic of primary TB. To better identify them, it is preferable to evaluate both the frontal and lateral views of the chest X-ray; the latter projection optimizes the visualization of the lymph nodes in the mediastinum (Figure 1).

As the disease progresses, intrathoracic lymph node lesions can compress the airways and cause atelectasis (more frequent in the upper and right middle lobes) or hyperinflation.

The pulmonary parenchymal involvement of TB manifests as pneumonia or bronchopneumonia not radiologically distinguishable from that caused by other pathogens. However, the persistence or worsening of these images despite appropriate antibiotic treatment raises suspicion of TB (Figure 2).

Single or multiple cavitations, observed within opacities with diffuse borders usually located in the upper lung fields, are highly suggestive of TB. They tend to occur in children older than 10 years with respiratory symptoms, where bacteriological confirmation is more common. Cavitations in lung lesions can also occur in young children with a progressing disease.

Another radiological pattern that prompts consideration of TB is the disseminated micronodules in both lung fields, characteristic of miliary TB (Figure 3).^{26, 27}

Many children have a history of previous respiratory episodes or pre-existing conditions such as asthma, post-infectious sequelae, HIV, or cystic fibrosis; in these cases, X-rays should be compared with the patient's previous imaging. When comparing images, it is important to consider differential diagnoses of complications that these conditions may present and look for images that raise suspicion of TB.

The ultrasound, performed with appropriate techniques for pediatric patients by a trained operator, can be useful for detecting adenomegaly and pleural effusion.²⁸

Chest CT scans increase diagnostic accuracy in cases where X-rays are inconclusive, especially for

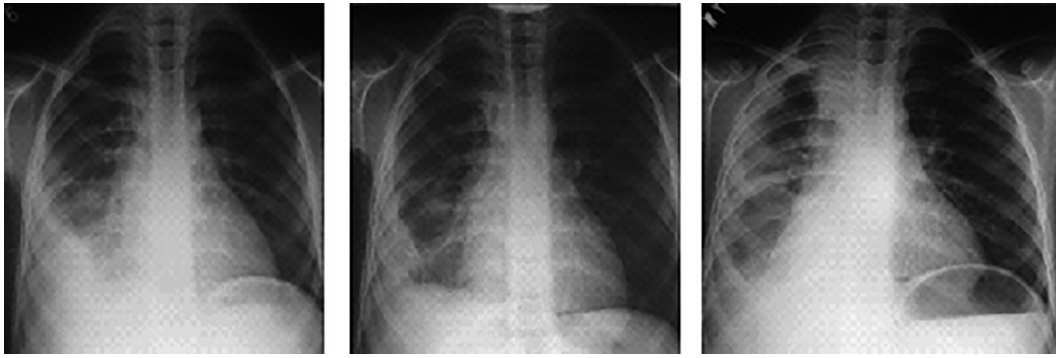


Figure 1. Evolution of a child with pulmonary and pleural TB treated as acute community-acquired pneumonia; it took two months to establish the diagnosis of TB.

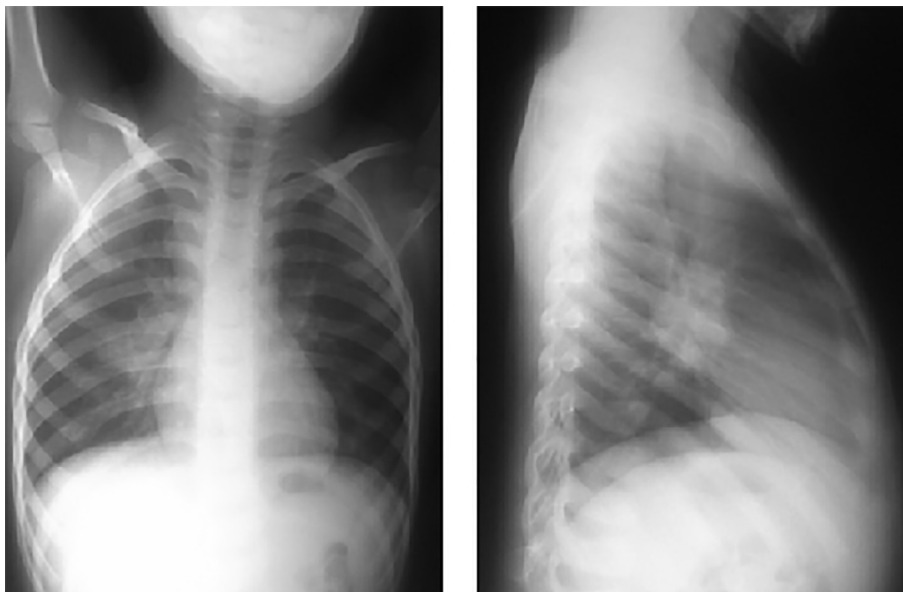


Figure 2. Chest X-ray, anterior and lateral views, a case of primary CTB.

detecting mediastinal adenomegalies. However, it is essential to consider the increased radiation to which the patient is exposed and the need for sedation or anesthesia to obtain good images in infants and young children.²⁹

Currently, automated, digital (computer-assisted), and tele-reading tools are being developed and optimized for pediatric patients to simplify the interpretation of imaging findings.²⁸

6.2 The role of the ultrasound

Dr. Elsa Bisero

Ultrasound is useful for identifying and characterizing lesions in the pleura, chest wall, diaphragm, and mediastinum. Its main advantages include the absence of ionizing radiation, real-time exploration capability, the possibility of conducting the study

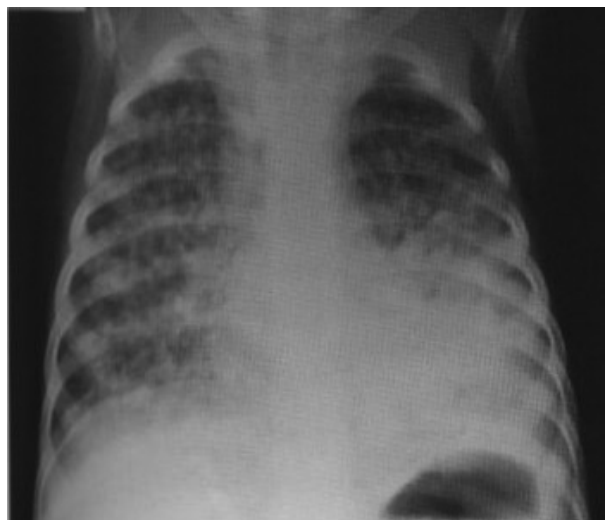

Figure 3. Primary pulmonary TB with hematogenous dissemination (miliary).

at the patient's bedside, evaluating the extent of the disease, and of performing sample collection, among others. These characteristics are particularly useful in individuals more susceptible to the adverse effects of radiation, such as children and pregnant women, or in patients with difficulty in moving, such as those admitted to intensive care units.³⁰

In thoracic diseases, ultrasound has played a secondary or practically nonexistent role. This is because 99 % of ultrasounds emitted by the ultrasound transducer are repelled at the interface between the pleura and the lung. This is due to the significant difference in acoustic impedance between soft tissues and air, as well as the substantial attenuation suffered by ultrasounds in their propagation through an air medium.³¹

Ultrasound in children is indicated in the following cases:

Study of serous membranes

a. Study of the pleura. It is more accurate (with 100 % sensitivity and 99.7 % specificity) than conventional X-rays for detecting pleural effusions, as it can visualize as little as 5 mL of fluid. The volume of the pleural effusion can be calculated using various equations based on the measurement of the lateral thickness of the fluid column, the height of the subpulmonic effusion, and the thickness of the lung covering. The simplest method involves multiplying the thickness of the lateral fluid column (in mm) by an empirical factor of 90, resulting in the volume of pleural effusion in milliliters ($r = 0.68$). It is a non-invasive, cost-effective procedure, widely used in pleural TB. The ultrasound appearance of a pleural effusion depends on its nature, cause, and chronicity. It allows the detection of septa (thick or thin and mobile), the characteristics of the content (internal echoes), thickening, obtaining histological samples of pleural lesions, with a success rate of 80 %, and dynamic monitoring of lesions. Pleural drainage techniques can be applied under ultrasound guidance, allowing the placement of smaller-caliber tubes with greater precision. Therefore, ultrasound-guided thoracentesis is a safe technique and can be performed in patients on mechanical ventilation.^{31, 32}

b. Study of the pericardium. In the diagnosis of pericardial effusion, color Doppler echocardiography is used to assess possible complications, such as cardiac tamponade or constrictive pericarditis.³³

c. Study of adenomegalies: Adenomegaly is defined as the presence of lymph nodes larger than 1 cm in diameter. The increase in lymph node volume is due to various mechanisms:

1. Repeated antigenic stimulation leading to lymphoid follicular hyperplasia with proliferation of intrinsic cells in the node (lymphocytes or plasma cells).
2. Infiltration by cells external to the node (Langenhans cell histiocytosis, deposition diseases).
3. Infiltration of polymorphonuclear cells (infectious adenitis).
4. Infiltration by tumor cells (in leukemia and solid tumors).

Due to their evolution, adenomegalies can be acute (less than 10 days of evolution), subacute (between 10 and 30 days), and chronic (more than 30 days of evolution). According to their location, they can be localized or generalized.

Thoracic adenomegalies receive lymph from the lung, heart, thymus, and esophagus. But in TB they can manifest with symptoms such as cough, wheezing, dysphagia, hemoptysis, airway erosion, atelectasis, neurological symptoms, and obstruction of large vessels (such as the superior vena cava, with potential life-threatening implications for the patient).

Ultrasound allows for the specification of size, shape, echogenicity, vascularity, content (solid or liquid), visualization of compressions, and access to certain areas of the mediastinum, especially the anterior compartment and the aortopulmonary window. It is used in cases with uncertain mediastinal images, (especially in children under 2 years old) through suprasternal and parasternal approaches. It has been demonstrated that up to 60 % of asymptomatic children with TB and chest X-rays interpreted as normal may have mediastinal adenopathies, especially subcarinal. The overall sensitivity of the ultrasound for the study of mediastinal adenopathies is 62 %, rising to 72 % when considering accessible areas of the lung. Guarda et al mention that adenopathies are present in 95 % of children, but X-rays may not always show them.³⁴⁻³⁶

The work of Lisa C. Ruby et al mentions that the proportion of children with lymphadenopathy detected by mediastinal ultrasound ranged from 15 % to 85 %, and studies including suprasternal and parasternal exploration achieved higher detec-

tion rates. Three retrospective studies reported mediastinal lymphadenopathy on ultrasound for the majority of cases that presented with a normal or inconclusive X-ray.³⁶

c. Study of abdominal structures: It allows visualizing ganglion structures, especially the groups for aortic, cava, and mesenteric. In TB, lymph nodes can be discrete or appear as opaque masses in clusters. It is common for enlarged nodes to contain hypoechoic areas or calcifications in the late stages of TB. Furthermore, the ultrasound allows highlighting caseating granulomas, especially in the liver and spleen, visualizing a primary nodal complex in the hepatic hilum (the only pathognomonic lesion of congenital TB). One drawback is that intestinal gas can make it difficult to see different structures.^{34, 37}

Endoscopic ultrasound (EUS) can help obtain images of lesions near the gastrointestinal lumen, which can be aspirated or biopsied using fine needle aspiration. Specific biopsies can be taken from the lymph nodes, the liver, and the pancreas. The ultrasound is useful for obtaining images of peritoneal tuberculosis.

6.3. Endobronchial ultrasound-guided transbronchial needle aspiration (EBUS-TBNA)

Endobronchial ultrasound (EBUS) is a minimally invasive technique that allows sampling of tissue from peripheral lung lesions or mediastinal/hilar masses, with high diagnostic precision and significantly lower morbidity and mortality compared to alternative approaches. In pediatric patients, EBUS-TBNA is primarily used to diagnose mediastinal adenopathies. This has led to increased diagnostic success with a reduced rate of complications. Due to the limited cooperation of children and concerns from their parents, sampling lymph nodes can be challenging. EBUS is a safe approach that demonstrates excellent sensitivity, specificity, and precision, making it a valuable tool for pediatricians.³⁷

A multicenter study retrospectively analyzed 67 pediatric participants who underwent endobronchial ultrasound-guided transbronchial needle aspiration (EBUS-TBNA) or endoscopic ultrasound with bronchoscope-guided fine needle aspiration (EUS-B-FNA). With the exception of two patients whose EBUS did not detect any significant lymph node, an adequate sample was obtained in 60 participants (92.3 %) and a diagnostic sample was ob-

tained in 37 participants (56.9 %). The sensitivity of EBUS-TBNA/EUS-B-FNA was 79.1 %, and the diagnosis was modified in 28 participants (41.8 %). The authors of this study considered EBUS-TBNA and EUS-B-FNA to be safe and effective diagnostic methods for the evaluation of children with mediastinal lymphadenopathy.³⁸

Advantages: EBUS can clearly show the relationship between blood vessels, lymph nodes, and lesions occupying space in the extraganglionic mediastinum.

Disadvantages: Although EBUS has many advantages, there are still some drawbacks. The specific structure of the bronchi in children poses some obstacles. The smaller size of the pediatric trachea and its deeper position limit the use of the method. The incidence of device breakage is high, and the cost of repair is high. Its application is contraindicated in patients with severely reduced lung function or respiratory failure, excessively deteriorated cardiac function, massive hemoptysis, and overall debilitating conditions. The diagnostic accuracy depends on many factors such as needle size, operator experience, and the location of lymph nodes.^{39, 40}

7. Microbiological testing/clinical scope of application

Dr. Graciela Luque

There are several challenges in the confirmation of the CTB diagnosis that arise from subtle or nonspecific radiographic results and from the paucibacillary nature of the disease. A confirmatory diagnosis is based on the direct detection of the pathogen; alternative approaches include detecting the immunoresponse or compatible histology. Direct pathogen-based tests include culture, nucleic acid amplification tests (NAAT), and bacilloscopies. To date, there isn't any accurate diagnostic test for CTB. Therefore, it is essential for physicians to recognize that TB is often a clinical diagnosis, since a negative test does not rule out the disease in children. Samples for culture from symptomatic children and those with manifestations of pulmonary or extrapulmonary lesions should always be studied.^{21, 41, 42}

Selection, collection and transportation of samples

It is essential to consider both the training of personnel collecting samples with standardized

protocols and providing explanations to the patient or their companion. The operator's skill, the quality of the obtained sample, and transportation are requirements that have an influence on the diagnosis.

Samples should be taken under respiratory isolation conditions, safeguarding the operator, in sterile containers, and should be transported to the laboratory in rigid, waterproof containers with a tight seal. The accompanying documentation must be clear and complete, including personal information, the type of sample being sent, conditions, diagnosis, and requested tests.⁴³

Efforts have been made to enhance the performance of the microbiological diagnosis using a wide variety of sample types and, even combine different methods or use sample pooling.^{44, 45}

Collecting a deep respiratory sample for culture from a young child poses additional challenges. Most children under 7 years old lack the cough strength or oral motor coordination to produce a high-quality expectorated sputum sample; they need semi-invasive techniques such as gastric aspiration/lavage or induced sputum (with or without nasopharyngeal aspiration). Both methods have similar microbiological performance, with a sensitivity between 30 % and 50 %.^{46, 47}

An alternative method for obtaining respiratory samples involves using the string test, where a gelatin capsule containing a nylon string (sweet string) is swallowed and later retrieved for culture.⁴⁸ Though promising, children under four years old have shown swallowing difficulties with this method, and it has been investigated in small groups with results similar to those of induced sputum.⁴⁹

Bronchoalveolar lavage (BAL) is an invasive procedure requiring specialized training, not well-tolerated in children. It is indicated for specific circumstances of suspicion with other negative samples, in the differential diagnosis, or when there is no response to treatment. Its performance depends on the type of lesion being studied and the classical or molecular isolation method.⁵⁰

Nasopharyngeal aspiration (NPA) and oral swab are still potential alternative samples. Further evidence is needed before it can be recommended as a sample collection method for children.⁴⁶

Fecal samples (stool tests) with buffers have low sensitivity in children (32 % to 68 %). They are primarily used in HIV-positive patients for molecular techniques.⁵¹

In extrapulmonary TB, the performance varies, and samples must be representative of the infection site, they shall be collected aseptically, and rapidly stored and transported to the laboratory to minimize multiplication of contaminating organs. Ideally, samples should reach the laboratory on the day of the collection. If transportation to the laboratory is delayed by more than an hour, the samples must be refrigerated at 4°C, both during transportation and upon arrival at the laboratory, until they are processed.⁵²

Cerebrospinal fluid (CSF) should be processed immediately or refrigerated for less than 12 hours. In the case of urine, two samples are obtained on consecutive days or every other day, and the largest possible volume is submitted (including the collection of several urine samples). The sample should be processed immediately because the acidic pH affects the viability of the bacillus. For other fluids (pleural, ascitic, synovial), the performance is not significantly higher than that from respiratory samples, but it improves when combined with biopsies or other non-microbiological methods.⁵³

In peripheral lymph node TB or abscesses, material is obtained through aspiration, fine needle aspiration, or biopsy. Cotton swabs or balls shouldn't be used. For tissue samples or biopsies, desiccation should be avoided by adding sterile distilled water.

In disseminated forms and in immunocompromised patients, blood cultures should also be performed.⁵²

8. Histopathology

Dr. Karina Melillo

The histopathological diagnosis is most frequently made in extrapulmonary TB.⁵⁴ The overall performance is not well characterized and depends to some extent on the experience of the operator and pathologist; the sensitivity and specificity may be hindered by other granulomatous processes.

The biopsy and autopsy allow us to determine the presence of acid-alcoholic resistant bacilli (AARB) through the histopathological study and confirmatory special studies, such as the Ziehl-Neelsen (ZN) technique.⁵⁴

The Kinyoun stain is similar to the ZN stain but does not use heat to enhance the uptake. Fluorochrome techniques with auramine-rhodamine are based on the same basic principle but allow for a faster and more convenient visualization of mycobacteria.

When examining sections stained with hematoxylin-eosin (H&E), granulomatous aggregates are often encountered. These aggregates consist of abundant histiocytes loaded with bacilli of approximately 3 μm or whirlwind-like granulomas with Langhans-type multinucleated giant cells having their nuclei arranged in a “C” shape, with central necrosis, not always accompanied by reactive lymphocytes (necrotizing granuloma). The presence of multiple granulomas in different evolutionary stages, with central caseous necrosis, suggests the diagnosis of TB, although multiple conditions can produce granulomas.⁵⁴ Exudative lesions (fibrinous exudates with alveolar invasion of neutrophils) are more common in immunocompromised individuals and have a worse prognosis. Both types of lesions may coexist, depending on the course of the disease.

DNA probe hybridization allows for the rapid identification of the species isolated in culture and even from paraffin-embedded tissue blocks.

Conflict of interest

The authors of this work have no conflicts of interest to declare.

REFERENCES

- World Health Organization. Rapid communication on updated guidance on the management of tuberculosis in children and adolescents. Geneva: World Health Organization; 2021. <https://www.who.int/publications/item/9789240033450>
- WHO consolidated guidelines on tuberculosis. Module 5: management of tuberculosis in children and adolescents. Geneva: World Health Organization; 2022. Licence: CC BY-NC-SA 3.0 IGO.
- Boletín N.º 5 Tuberculosis y lepra en la Argentina Año V - Coordinación de tuberculosis y lepra. Dirección de respuesta al VIH, ITS, hepatitis virales y tuberculosis, Ministerio de Salud, Argentina. Marzo de 2022.
- WHO operational handbook on tuberculosis. Module 2: screening - systematic screening for tuberculosis disease. Geneva: World Health Organization; 2021. License: CC BY-NC-SA 3.0 IGO. <https://www.who.int/publications/item/9789240022676>.
- Gutiérrez D, Vásquez A. La tuberculosis infantil: Enfoque epidemiológico y nuevas alternativas de diagnóstico. *Rev Cs Farm y Bioq (Perú)* 2014;2:93-100. Disponible en: http://www.scielo.org.bo/scielo.php?script=sci_arttext&pid=S2310-02652014000100011&lng=es. ISSN 2310-0265
- Holcberg M, Zabala C, Gutiérrez S, Sisto G, Sosa M, Giachetto G. Prevalencia y características de niños con tuberculosis diagnosticados a partir de un caso índice. *Uruguay* 2012-2014. *Arch Pediatr Urug* 2016;87:S3-S10. Disponible en: http://www.scielo.edu.uy/scielo.php?script=sci_arttext&pid=S1688-12492016000500001&lng=es
- Pérez-Vélez CM, Marais BJ. Tuberculosis in children. *N Engl J Med* 2012;367:348-61. <https://doi.org/10.1056/NEJMra1008049>.
- Martínez L, Cords O, Horsburgh CR, Andrews JR. Pediatric TB Contact Studies Consortium. The risk of tuberculosis in children after close exposure: a systematic review and individual-participant meta-analysis. *Lancet* 2020; 395:973-84. [https://doi.org/10.1016/S0140-6736\(20\)30166-5](https://doi.org/10.1016/S0140-6736(20)30166-5).
- Roya-Pabon CL, Pérez-Vélez CM. Tuberculosis exposure, infection and disease in children: a systematic diagnostic approach. *Pneumonia* 2016;8:23. <https://doi.org/10.1186/s41479-016-0023-9>.
- Marais BJ, Gie RP, Hesselning AC, et al. A refined symptom-based approach to diagnose pulmonary tuberculosis in children. *Pediatrics*. 2006;118: e1350-9. <https://doi.org/10.1542/peds.2006-0519>.
- Vonasek B, Ness T, Takwoingi, et al. Screening tests for active pulmonary tuberculosis in children. *Cochrane Database Syst Rev* 2021;6::CD013693. <https://doi.org/10.1002/14651858.CD013693.pub2>.
- Cruz Anleu ID, Velásquez Serratos JR. Tuberculosis infantil. ¿Cómo diagnosticarla? [Childhood tuberculosis. How to diagnose it?]. *Arch Argent Pediatr*. 2012;110:144-51. <https://doi.org/10.5546/aap.2012.144>.
- Ramos Amador JT, Berzosa Sánchez A., Callejas Caballero I, Illán Ramos M.. Tuberculosis pulmonar en Pediatría. *Pediatr Integral* 2021;15:76-90.
- Marais BJ, Pai M. Recent advances in the diagnosis of childhood tuberculosis. *Arch Dis Child* 2007;92:446-52. <https://doi.org/10.1136/adc.2006.104976>.
- Migliori GB, Ong C, Petrone L, D'Ambrosio L, Centis R, Gotelli D. The definition of tuberculosis infection based on the spectrum of tuberculosis disease. *Breathe* 2021;17 210079. <https://doi.org/10.1183/20734735.0079.2021>.
- Vieira JL, Foschiera L, Ferreira ICS, Chakr VC. Performance of the quantification of adenosine deaminase and determination of the lactate dehydrogenase/adenosine deaminase ratio for the diagnosis of pleural tuberculosis in children and adolescents. *J Bras Pneumol*. 2021;47:e20200558. <https://doi.org/10.36416/1806-3756/e20200558>.
- Zhang M, Li D, Hu ZD, Huang YL. The diagnostic utility of pleural markers for tuberculosis pleural effusion. *Ann Transl Med* 2020;8:607-18. <https://doi.org/10.21037/atm.2019.09.110>.
- Sociedad Argentina de Pediatría. Comité Nacional de Neumología. Coordinadora: Dra. Norma González. Criterios de diagnóstico y tratamiento de la tuberculosis infantil. Consenso. *Arch Argent Pediatr* 2016;114:189. <https://doi.org/10.5546/aap.2016.189>.
- Cobat A, Poirier C, Hoal E, et al. Tuberculin Skin Test Negativity Is Under Tight Genetic Control of Chromosomal Region 11p14-15 in Settings With Different Tuberculosis Endemicities. *J Infect Dis* 2015;211:317-21. <https://doi.org/10.1093/infdis/jiu446>
- Lewinsohn DM, Leonard MK, Lo Bue PA, et al. Official American Thoracic Society/Infectious Diseases Society of America/Centers for Disease Control and Prevention Clinical Practice Guidelines: Diagnosis of Tuberculosis in Adults and Children. *Clin Infect Dis*. 2017;64:e1-e33. <https://doi.org/10.1093/cid/ciw694>.
- Chiappini E, Storelli F, Tersigni C, Venturini E, Martino M, Galli L. QuantiFERON-TB Gold In-Tube test performance in a large pediatric population investigated for suspected

- tuberculosis infection. *Paediatr Respir Rev* 2019;23:36-47. <https://doi.org/10.1016/j.prrv.2019.03.010>.
22. Ruhwald M, Aggerbeck H, Gallardo RV, et al. Safety and efficacy of the C-Tb skin test to diagnose *Mycobacterium tuberculosis* infection, compared with an interferon γ release assay and the tuberculin skin test: a phase 3, double-blind, randomized, controlled trial. *Lancet Respir Med* 2017;5:259-68. [https://doi.org/10.1016/S2213-2600\(16\)30436-2](https://doi.org/10.1016/S2213-2600(16)30436-2).
23. Slogotskaya L, Bogorodskaya E, Ivanova D, Sevostyanova T. Comparative sensitivity of the test with tuberculosis recombinant allergen, containing ESAT6-CFP10 protein, and Mantoux test with 2 TU PPD-L in newly diagnosed tuberculosis children and adolescents in Moscow. *PLoS ONE* 2018. 13: e0208705. <https://doi.org/10.1371/journal.pone.0208705>
24. Starshinova A, Dovgalyk I, Malkova A et al. Recombinant tuberculosis allergen (Diaskintest®) in tuberculosis diagnostic in Russia (MetaAnalysis). *Int J Mycobacteriol* 2020; 9:335-46. https://doi.org/10.4103/ijmy.ijmy_131_20.
25. Zellweger JP, Heinzer R, Touray M, Vidondo B, Altpeter E. Intra-observer and overall agreement in the radiological assessment of tuberculosis. *Int J Tuberc Lung Dis*. 2006;10:1123-6.
26. Concepción ND, Laya BF, Andronikou S, et al.. Standardized radiographic interpretation of thoracic tuberculosis in children. *Pediatr Radiol*. 2017;47:1237-48. <https://doi.org/10.1007/s00247-017-3868-z>.
27. Jain SK, Andronikou S, Goussard P, et al. Advanced imaging tools for childhood tuberculosis: potential applications and research needs. *Lancet Infect Dis*. 2020;20: e289-e297. [https://doi.org/10.1016/S1473-3099\(20\)30177-8](https://doi.org/10.1016/S1473-3099(20)30177-8).
28. Buonsenso D, Pata D, Visconti E, et al. Chest CT Scan for the Diagnosis of Pediatric Pulmonary TB: Radiological Findings and Its Diagnostic Significance. *Front. Pediatr*. 2021; 9:583197. <https://doi.org/10.3389/fped.2021.583197>.
29. De La Quintana Gordon FB, Nacarino Alcorta B. Ecografía pulmonar básica. Parte 1. Ecografía pulmonar normal y patología de la pared torácica y la pleura. *Rev Esp Anestesiol Reanim* 2015;62: 322-36. <https://doi.org/10.1016/j.redar.2015.02.003>
30. Vollmer I, Gayete A. Ecografía torácica. *Arch Bronconeumol*. 2010;46:27-34. <https://doi.org/10.1016/j.arbres.2008.12.004>.
31. Oyonarte WM. Enfoque diagnóstico en el paciente con derrame pleural. *Rev Med Clin Condes* - 2015;26:313-24. <https://doi.org/10.1016/j.rmclc.2015.06.008>
32. Ramírez-Lapausa M., Menéndez-Saldaña A., Noguerado-Asensio A. Tuberculosis extrapulmonar, una revisión. *Rev Esp Sanid Penit* 2015;17:3-11. <https://doi.org/10.4321/S1575-06202015000100002>.
33. Bilbao Sustacha JA, Peix Sambola MA, Alonso Martín DE, Díaz Lázaro J. Aplicación de la ecografía clínica pediátrica en Atención Primaria. En: AEPap (ed.). Congreso de Actualización Pediatría 2019. Madrid: Lúa Ediciones 3.0; 2019. p. 495-506.
34. Tovar Díaz M, Tang Velásquez AM, Concha Mendoza ND. Tuberculosis extrapulmonar en pediatría: un reto diagnóstico. *Rev. Medicas UIS* 2013;26:45-58. Disponible en: <https://revistas.uis.edu.co/index.php/revistamedicasuis/article/view/3582>.
35. Guarda ME, Kreft J. Tuberculosis en el niño ¿Cómo se diagnosticar? *Rev Med Clin Condes* - 2017;28:104-10. <https://doi.org/10.1016/j.rmclc.2017.02.011>.
36. Ruby LC, Heuvelings CC, Grobusch MP, Andronikou S, Bé-lard S. Transthoracic mediastinal ultrasound in childhood tuberculosis: A review. *Paediatr Respir Rev*. 2022;41:40-8. <https://doi.org/10.1016/j.prrv.2020.11.002>.
37. Steinfort DP, Wurzel D, Irving LB, Ranganathan SC. Endobronchial ultrasound in pediatric pulmonology. *Pediatr Pulmonol*. 2009;44:303-8. <https://doi.org/10.1002/ppul.20991>.
38. Dhooria S, Madan K, Pattabhiraman V, et al. A multicenter study on the utility and safety of EBUS-TBNA and EUS-B-FNA in children. *Pediatr Pulmonol*. 2016;51:1031-9. <https://doi.org/10.1002/ppul.23415>.
39. Park M, Owles H, Williams A, Williams B, Whittaker E, Kon OM. Pediatric Endobronchial Ultrasound-Transbronchial Needle Aspiration Under Conscious Sedation for Suspected Tuberculosis in London. *Pediatr Infect Dis J*. 2020;39:e329-31. <https://doi.org/10.1097/INF.0000000000002819>
40. Gulla KM, Gunathilaka G, Jat KR et al. Utility and safety of endobronchial ultrasound-guided transbronchial needle aspiration and endoscopic ultrasound with an echobronchoscope-guided fine needle aspiration in children with mediastinal pathology. *Pediatr Pulmonol*. 2019;54:881-5. <https://doi.org/10.1002/ppul.24313>.
41. Cuevas LE, Petrucci R, Swaminathan S. Tuberculosis diagnostics for children in high-burden countries: what is available and what is needed. *Paediatr Int Child Health*. 2012;32(Suppl 2):S30-7. <https://doi.org/10.1179/2046904712Z.0000000000076>.
42. Ministerio de Salud. Gobierno de El Salvador. Guía clínica para la atención pediátrica de la tuberculosis y la coinfección TB-VIH. San Salvador, El Salvador 2021. <http://asp.salud.gov.sv/regulacion/default.asp>
43. Starke J, Cruz AI. Diagnosing Childhood Tuberculosis: A Small Step Forward. *JAMA Pediatrics* 2021;175: e206078. <https://doi.org/10.1001/jamapediatrics.2020.6078>
44. Datta S, Shah L, Gilman RH, Evans CA. Comparison of sputum collection methods for tuberculosis diagnosis: a systematic review and pairwise and network meta-analysis. *Lancet Glob Health* 2017;5:e760-71. [https://doi.org/10.1016/S2214-109X\(17\)30201-2](https://doi.org/10.1016/S2214-109X(17)30201-2).
45. Ioos V, Cordel H, Bonnet M. Alternative sputum collection methods for diagnosis of childhood intrathoracic tuberculosis: a systematic literature review. *Arch Dis Child* 2019;104:629-35. <https://doi.org/10.1136/archdischild-2018-315453>.
46. Ruiz Jiménez M, Guillén Martín S, Prieto Tato LM, et al. Induced sputum versus gastric lavage for the diagnosis of pulmonary tuberculosis in children. *BMC Infect Dis*. 2013; 13:222-8. <https://doi.org/10.1186/1471-2334-13-222>.
47. Tafur KT, Coit J, Leon SR, et al. Feasibility of the string test for tuberculosis diagnosis in children between 4 and 14 years old. *BMC Infect Dis*. 2018;18:574-81. <https://doi.org/10.1186/s12879-018-3483-0>.
48. Imperiale BR, Nieves C, Mancino B, et al. String test: A new tool for tuberculosis diagnosis and drug-resistance detection in children. *Int J Mycobacteriol*. 2018;7:162-6. https://doi.org/10.4103/ijmy.ijmy_54_18.
49. Goussard P, Retief F, Burke J, Malherbe A, Janson J. The role of bronchoscopy in the diagnosis and manage-

- ment of pediatric pulmonary tuberculosis. *Ther Adv Infectious Dis* 2021;8:1-19. <https://doi.org/10.1177/20499361211037168>
50. Mesman AW, Rodríguez C, Ager E, Coit J, Trevisi L, Franke MF. Diagnostic accuracy of molecular detection of *Mycobacterium tuberculosis* in pediatric stool samples: A systematic review and meta-analysis. *Tuberculosis (Edinb)*. 2019;119:101878. <https://doi.org/10.1016/j.tube.2019.101878>
51. Dunn JJ, Starke JR, Revell PA. Laboratory diagnosis of *Mycobacterium tuberculosis* infection and disease in children. *J Clin Microbiol* 2016; 54:1434-41. <https://doi.org/10.1128/JCM.03043-15>. 10.1016/j.jctube.2020.100164
52. Foppiano Palacios C, Saleeb PG. Challenges in the diagnosis of tuberculous meningitis. *J Clin Tuberc Other Mycobact Dis* 2020;20:100164. <https://doi.org/10.1016/j.jctube.2020.100164>
53. Bagdia M, Bijwe S, Hirani N, Joshi A, Chowdhary A, Agrawal M, Bagdia A. Lab Diagnosis of Extra Pulmonary Tuberculosis: Comparison of Histopathology, Cytology, ZeihlNeelsen stain and Light Emission Diode Microscopy with Culture and Nucleic Acid Amplification Tests. *Int J Cur Res Rev* 2018; 10:15-9. <https://doi.org/10.7324/IJCRR.2018.10803>
54. Shah KK, Pritt BS, Alexander MP. Histopathologic review of granulomatous inflammation. *J Clin Tuberculosis Other Mycobacterial Dis* 2017; 7:1-12. <https://doi.org/10.1016/j.jctube.2017.02.001>